



## The Efficacy of Alcoholic Extracts of *Morus Macroura* (Mulberries), *Lepidium Sativum* (Garden Cress Seeds) and Diclazuril Against *E. stiedae* in Experimentally Infected Rabbits

Marwa Saleh<sup>1\*</sup>, Mohamed Ramadan<sup>1</sup>, Reham Elmadawy<sup>1</sup>, Mai Morsi<sup>2</sup> and Lubna El-Akabawy<sup>1</sup>

<sup>1</sup>Parasitology Department, Faculty of Veterinary Medicine, Benha University, Benha 13736, Egypt

<sup>2</sup>Pharmacognosy Department, Faculty of Pharmacy Zagazig University, Zagazig 44519, Egypt

\*Corresponding author: [marwa3wade@gmail.com](mailto:marwa3wade@gmail.com)

Article History: 23-110

Received: 13-Jan-23

Revised: 13-Mar-23

Accepted: 23-Mar-23

### ABSTRACT

The current study aimed to assess the protective role of *Morus Macroura* (Mulberries), *Lepidium Sativum* (Garden Cress Seeds) against *E. stiedae* in experimentally infected rabbits. Fifty rabbits were randomly divided into five groups: G1 and G2 rabbits were supplemented with *M. Macroura* and *L. sativum*; respectively with a daily dose of 300mg/kg BW which began one week before infection and continued daily till the end of the experiment. G3 was administered diclazuril (1ppm) for only one week before infection; G4 was kept as infected- non-treated (CP) and G5 was kept as untreated- uninfected (CN). On 7<sup>th</sup> day of the experiment, all groups except G5 were orally infected with 10<sup>4</sup> sporulated oocysts of *E. stiedae* using a stomach tube. The following up of the clinical symptoms, weight, fecal oocysts count, hematological and biochemical parameters (liver, and kidney function) were done for each rabbit throughout the experiment, in addition the lesion score was done after PM examination and histopathology of the liver. The results revealed a significant improvement in clinical signs in botanical plant and diclazuril treated groups, with an improvement in body weight, a highly significant reduction in oocysts shedding with a significant improvement of CBC and liver and kidney enzymes compared to CP group. In conclusion, both *M. Macroura* and *L. Sativum* could equally compete with the chemical drug (Diclazuril) in their anti-coccidial effect on *E. stiedae* and can be used as a safe useful alternative remedy to control rabbit coccidiosis.

**Key words:** *Coccidiosis, Morus macroura, Lepidium sativum, Alcoholic extract.*

### INTRODUCTION

Coccidiosis is a major global concern in rabbit farms, affecting rabbit growth performance and feed consumption it also causing significant morbidity and mortality (Abdel Megeed et al. 2005; Khater et al. 2020). Natural rabbit coccidiosis infection reached 70% in Egyptian rabbit herds (El-Shahawi et al. 2012), and it is accompanied by two forms: hepatic, caused by *E. stiedae*, the most prevalent species to infect rabbits and cause death (Al-Rukibat et al. 2001; Bochyńska et al. 2022), and intestinal, which is caused by other *Eimeria* species (Çam et al. 2008; Rabie et al. 2022). Clinical signs of hepatic illness include lethargy, constipation or diarrhea, decreased food intake, ascites, enlarged liver, icterus, an enlarged abdomen, and ultimately death (Karaer 2001; AbouLaila et al. 2020).

Control of coccidiosis is mostly dependent on chemoprophylaxis using chemotherapeutic compounds (Dalloul and Lillehoj 2006); however, managerial skills are also known to be important in enhancing the anti-coccidial effects of these compounds (Tewari and Maharana 2011). Although these chemotherapeutics were initially effective, the development of resistance to *Eimeria* species rendered them less effective (Abbas et al. 2017). Furthermore, most present anti-coccidials are expensive and have undesirable side effects (El-Akabawy et al. 2004; Dalloul and Lillehoj 2006; Kadykalo et al. 2018; El-Ghany 2021). Furthermore, drug residues in meat products may be extremely dangerous for humans. As a result, there is a growing interest in creating unique techniques to solve this problem and reduce economic losses. Several techniques, such as antioxidant-rich botanical extracts, have been established as effective anti-coccidial agents with comparable efficacy to synthetic

**Cite This Article as:** Saleh M, Ramadan M, Elmadawy R, Morsi M and El-Akabawy L, 2023. The efficacy of alcoholic extracts of *Morus macroura* (mulberries), *Lepidium sativum* (garden cress seeds) and diclazuril against *E. stiedae* in experimentally infected rabbits. International Journal of Veterinary Science x(x): xxxx. <https://doi.org/10.47278/journal.ijvs/2023.049>

medications (Aboelhadid et al. 2019; Abu El Ezz et al. 2020; Han et al. 2022).

Some botanical drugs such as *Morus macroura* and *Lepidium sativum* are reported to be of great medical importance (Tirtha 2005; Teklehaymanot et al. 2007) and comprise several active compounds (Zia-Ul-Haq et al. 2012; Nile and Park 2014; Skrovankova et al. 2015). Moreover, *L. sativum* showed potential anti-coccidial activity against avian coccidiosis (Adamu and Boonkaewwan 2014), but there is no previous study about *M. macroura* is known regarding their effect on hepatic coccidiosis. So, in this work, we introduce for the first time the effects of the Alcoholic extract of *M. macroura* and *L. sativum* against *E. stiedae* infection in rabbits as compared to diclazuril (common chemical anti-coccidial drug) and the effect of these extracts on performance, hematological and biochemical parameters were tested in experimentally infected rabbits with *E. stiedae*.

## MATERIALS AND METHODS

### Source of *E. Stiedae*

*Eimeria stiedae* oocysts used in this study were kindly obtained from Dr. Nagwa El-Hawary, Faculty of Veterinary Medicine, Kafr El-Sheikh, and Department of Parasitology.

### Propagation and Isolation of Oocysts

Five rabbits were inoculated orally by *E. stiedae* sporulated oocysts. Accordingly, these rabbits were euthanized after 20 days, then the livers and gallbladders were collected, minced, and digested in 0.25% trypsin in normal saline. The digested materials were sieved, centrifuged at 2000rpm for 10min, and washed several times with saline solution, then examined microscopically for *E. stiedae* oocysts according to (Levine 1985). The gained oocysts were morphologically identified and preserved in a 2.5% potassium dichromate solution for sporulation. The Sporulated oocysts were counted by the McMaster counting technique and stored at 4°C till use (Levine 1985).

### Experimental Animals

Fifty New Zealand rabbits aged 35-37 days and weighing 500–800g were randomly divided into 5 groups (10 rabbits in each group). During the experimental period, rabbits were housed individually in metal cages. Each cage had a metallic grid on its bottom part to keep rabbits from coming into contact with their own feces. Direct fecal analysis followed by flotation technique was monitored daily for two successive weeks to confirm that the rabbits were free from any coccidial infection, before applying the intended experiments.

### Preparation of Botanical Extracts

#### Ethanolic Extract of *Morus Macroura*

The plant extract was kindly provided by Dr. Mai. M. Karousa, Faculty of Pharmacy, Zagazig University, Pharmacognosy Department. The extract was prepared from dried stems, leaves, and fruits of *M. macroura* Miq, which were separately macerated with 80% aqueous ethanol at room temperature (Hamdan et al. 2022). A

mixture of the yielded extracts was weighted and used in the experiment.

#### Ethanolic Extract of *Lepidium sativum*

The plant was obtained from a local market and was authenticated by a botanist. The extraction procedure was carried out in Nawah Scientific center, where 2kg of the plant were mixed with 5500mL ethanol (83%), then sonicated for 30 minutes and macerated and left for one day before filtration. The process was repeated two more times. Then the extracts were collected and dried under a vacuum at 50°C. The resultant was dark red extracted residues weighing 35g which were stored at 4°C for till use.

### Experimental Design

The experiment was carried out at Laboratory Animal Research Center, Benha University, Faculty of Veterinary Medicine. All procedures performed in this experiment were approved by Institutional Animal Care and Use Committee (IACUC), Benha University and followed National Institute of Health rules in Egypt (Ethical No. BUFVTM24-10-22).

The rabbits (n=50) were classified randomly into five groups (ten rabbits each), the rabbits in G1, and G2 were supplemented in drinking water with *Morus macroura*, and *Lepidium sativum* respectively in a daily dose of 300mg/kg BW for one week before infection. Rabbits in G3 were administrated diclazuril (Pharma Swede-Egypt) at a dose of 1 ppm in drinking water (Vanparijs et al. 1989) for only seven days before infection. After one week of botanical plant treatment, each rabbit in all groups except G5 were orally inoculated with 10<sup>4</sup> sporulated oocysts of *E. stiedae* using a stomach tube (Hassan et al. 2016). The treatment with plant extracts continued daily post-infection and extended for 40 days. While rabbits in G4 were kept as untreated-infected (control positive), moreover, rabbits in G5 remain untreated /uninfected (control negative).

### Evaluation Parameters

The following parameters were assessed to evaluate effect of used botanical plants:

#### Clinical Signs of Hepatic Coccidiosis

All the rabbits in different groups were clinically examined daily for noticing the mortalities among rabbits and observation of coccidiosis symptoms such as lack of appetite, dullness, and abdominal distention.

#### Fecal Analysis and Oocysts Count

Fresh fecal samples were assembled daily from each rabbit in each group into sterile separate containers. Each sample was microscopically examined till the end of the experiment to evaluate the pre-patent period and the number of *E. stiedae* oocysts per gram using McMaster counting chamber (Long et al. 1976).

#### Body Weight

The weight of each rabbit in each group was recorded at the beginning of the experiment and then weekly till the end of the experiment (40 DPI).

### Gross lesion and Histopathological Examinations

At the end of the experiment, each rabbit was sacrificed, and its liver was examined at PM for the presence of a characteristic hepatic nodules of *E. stiedae*. For histopathological examination, liver specimens were immediately fixed in 10% neutral formalin, embedded into paraffin wax, sectioned to 5µm thickness, stained with hematoxylin-eosin stain, and inspected microscopically for presence of *E. stiedae* stages (Culling 1983).

### Biochemical and Hematological Parameters

For CBC analysis (Leukocyte, lymphocyte, erythrocyte counts, and Hb), blood samples were collected from each rabbit in each group into EDTA-coated tubes on the 7<sup>th</sup> and 40<sup>th</sup> days of the experiment. Furthermore, other blood samples were used for separation of the serum for biochemical assessment of liver function including ALT, AST, GGT, and albumin and kidney function including creatinine and urea.

### Statistical Analysis

Statistical analysis was carried out using two-way ANOVA using SPSS, ver. 25. Data were treated as a complete randomization design according to Steel (Steel and Torrie 1997). Multiple comparisons were carried out by applying the Duncun test and the significance level was set at P<0.05.

## RESULTS

Concerning clinical signs, G1 (*M. macroura* treated group), and G2 (*L. sativum* treated group) showed no symptoms of hepatic coccidiosis or any clinical abnormalities throughout the experiment compared to G3 (Diclazuril treated group) which its animals remained healthy and showed normal appetite throughout the experiment, but slight dullness was exhibited at the end of the experiment. On the other hand, the rabbits in G4 (CP) showed signs of depression, rough coat, decrease appetite, loss of body weight, and abdominal distension. Rabbits in

G5 (CN) remained normal without any symptoms of the disease. No Mortality was recorded in both G1, G2, and G5 during the entire experiment, only one death case was recorded in G3 and G4 on the 32<sup>nd</sup> and on the 40<sup>th</sup> DPI; respectively.

### Oocysts Counts

Oocysts shedding was observed in the feces, on 17<sup>th</sup> DPI (pre-patent period), all treated groups (G1, G2, G3) showed a significant decrease in oocysts count from 17<sup>th</sup> to 32<sup>nd</sup> DPI compared to G4 (CP). With tool plants showed a significant superiority (P<0.05) in reduction of oocysts count in the treated groups (G1, G2) on 28<sup>th</sup>, 29<sup>th</sup>, 30<sup>th</sup> and 32<sup>nd</sup> DPI as compared with to G3 (Diclazuril group). Generally, G2 could surpass the other groups as it could significantly reduce the oocysts count on 28<sup>th</sup>, 29<sup>th</sup>, 30<sup>th</sup> and 31<sup>st</sup> days as compared with G1, G3, and G4 as shown in Table 1.

### Body Weight Gain

Regarding body weight gain of rabbits, a significant increase (P<0.05) in the body weight of rabbits was noticed in G3 which showed the heaviest body gain from zero day till day 40<sup>th</sup> of the experiment compared to other treated and CP groups. Fortunately, both G1 and G2 could achieve a significant increase in rabbit weight (1043±87.34 and 1385.71±105.53; respectively) on the 40<sup>th</sup> of the experiment as compared with G4 (1045.00±50.03). Mostly, the body weight of rabbit in G3, followed by G2 could outperform the body weight of the rabbits in G1 and G4 (Table 2).

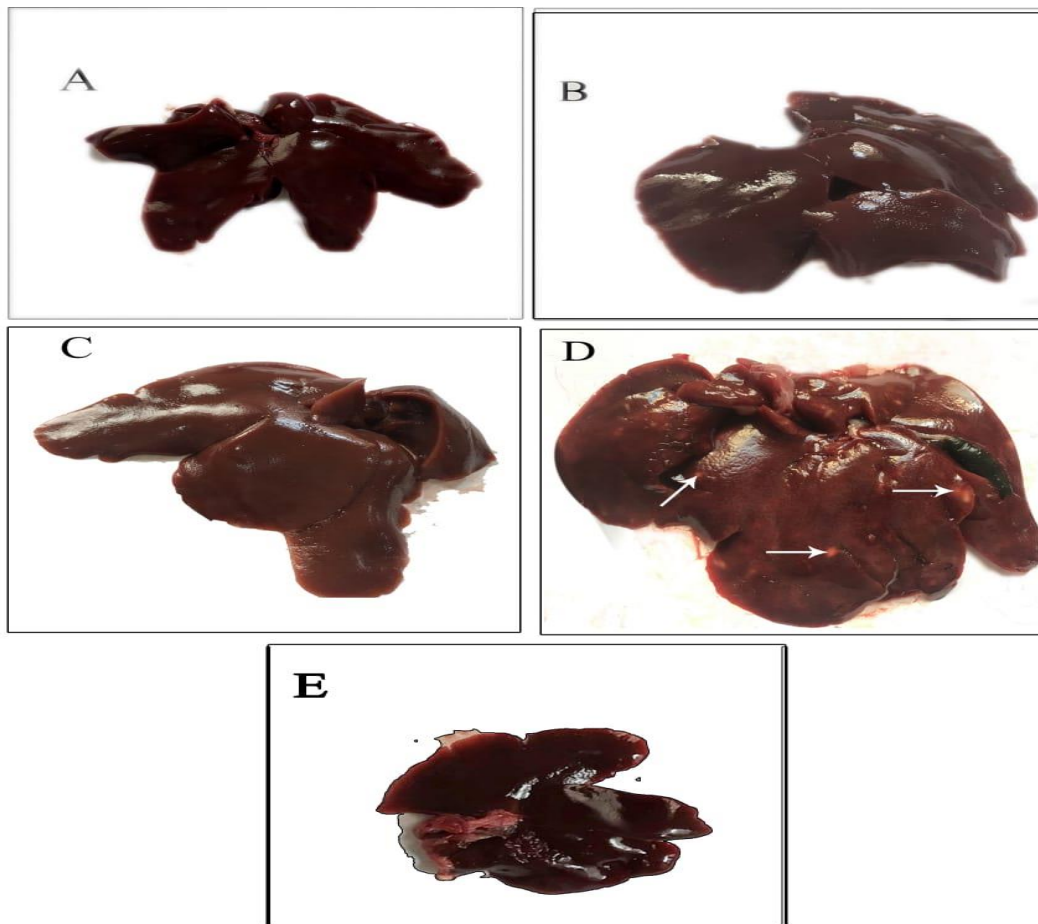
### Gross Lesions of the Liver

On 40<sup>th</sup> day of the experiment, the livers of rabbits in G1 were slightly enlarged without obvious nodules, while in G2 and G3, they were moderately enlarged as compared to the livers in G4 (CP) which showed extensive enlargement with a pale appearance and studded whitish nodules with distended gall bladders. In G5 (CN), the rabbit's livers appeared normal without any changes as shown in Fig. 1.

**Table 1:** Daily oocysts count (mean±SE) in different groups of rabbit

Day-Post Infection (DPI)	Groups				
	G1	G2	G3	G4	G5
17	3.38±0.08 <sup>bcC</sup>	2.95±0.06 <sup>cdD</sup>	2.56±0.18 <sup>deE</sup>	3.92±0.08 <sup>efA</sup>	0±0 <sup>aF</sup>
18	3.53±0.11 <sup>aB</sup>	3.62±0.04 <sup>aB</sup>	2.52±0.21 <sup>eC</sup>	4.50±0.03 <sup>bA</sup>	0±0 <sup>aD</sup>
19	3.29±0.14 <sup>cC</sup>	2.95±0.08 <sup>cdE</sup>	2.70±0.03 <sup>cdE</sup>	5.01±0.07 <sup>aA</sup>	0±0 <sup>aF</sup>
20	3.14±0.08 <sup>deC</sup>	2.82±0.11 <sup>dD</sup>	2.35±0.17 <sup>fE</sup>	4.98±0.02 <sup>aA</sup>	0±0 <sup>aF</sup>
21	2.98±0.05 <sup>efD</sup>	3.18±0.06 <sup>bc</sup>	2.63±0.23 <sup>deE</sup>	4.10±0.04 <sup>deA</sup>	0±0 <sup>aF</sup>
22	3.27±0.14 <sup>cdB</sup>	2.75±0.38 <sup>eC</sup>	2.59±0.29 <sup>deD</sup>	3.87±0.05 <sup>fgA</sup>	0±0 <sup>aE</sup>
23	3.05±0.07 <sup>eC</sup>	3.29±0.25 <sup>bb</sup>	2.83±0.13 <sup>cd</sup>	3.55±0.12 <sup>ia</sup>	0±0 <sup>aF</sup>
24	3.00±0.04 <sup>efC</sup>	3.62±0.18 <sup>aB</sup>	2.71±0.36 <sup>cdD</sup>	3.66±0.05 <sup>hiAB</sup>	0±0 <sup>aE</sup>
25	2.74±0.23 <sup>gD</sup>	3.00±0.04 <sup>cb</sup>	2.86±0.22 <sup>cC</sup>	3.67±0.04 <sup>hiA</sup>	0±0 <sup>aE</sup>
26	3.03±0.08 <sup>eC</sup>	3.75±0.04 <sup>ab</sup>	2.81±0.07 <sup>cd</sup>	3.91±0.06 <sup>fgA</sup>	0±0 <sup>aE</sup>
27	3.22±0.08 <sup>cdC</sup>	3.34±0.18 <sup>bb</sup>	2.35±0.35 <sup>fD</sup>	3.95±0.04 <sup>efA</sup>	0±0 <sup>aE</sup>
28	2.35±0.17 <sup>hE</sup>	2.99±0.20 <sup>fF</sup>	3.70±0.09 <sup>aB</sup>	4.33±0.04 <sup>ca</sup>	0±0 <sup>aF</sup>
29	2.85±0.03 <sup>fC</sup>	2.55±0.03 <sup>fD</sup>	3.65±0.12 <sup>abB</sup>	4.19±0.04 <sup>cdA</sup>	0±0 <sup>aF</sup>
30	3.47±0.06 <sup>abC</sup>	2.24±0.24 <sup>eE</sup>	3.62±0.13 <sup>abB</sup>	3.75±0.04 <sup>ghA</sup>	0±0 <sup>aF</sup>
31	3.62±0.06 <sup>aB</sup>	2.27±0.13 <sup>gD</sup>	2.00±0.17 <sup>gE</sup>	3.90±0.03 <sup>fgA</sup>	0±0 <sup>aF</sup>
32	2.32±0.19 <sup>hd</sup>	2.37±0.19 <sup>gD</sup>	3.49±0.03 <sup>bb</sup>	3.85±0.04 <sup>fgA</sup>	0±0 <sup>aE</sup>

a, b and c: There is no significant difference (P>0.05) between any two means, within the same column have the same superscript letter. A, B and C: There is no significant difference (P>0.05) between any two means, within the same row same superscript letter. G1: *M. macroura* treated group, G2: *L. sativum* treated group, G3: Diclazuril group, G4: control positive (CP), G5: control negative (CN).



**Fig. 1:** The gross appearance of the liver of rabbits in different groups, (A): G1 treated with *M. macroura*. (B): G2 treated with *L. sativum*. (C): G3 diclazuril group. (D): G4 (control positive), white arrows refer to typical nodules in the liver of rabbits caused by *E. stiedae*. (E): G5 (control negative).

**Table 2:** Body weight of rabbits in different groups

Day	Groups				
	G1	G2	G3	G4	G5
0	930.00±20.11 <sup>Ca</sup>	912.00±32.72 <sup>Cb</sup>	1368.00±70.63 <sup>Aa</sup>	832.00±58.99 <sup>Ca</sup>	1379.00±62.42 <sup>Ab</sup>
7	979.00±51.78 <sup>Ba</sup>	1010.00±56.16 <sup>Bb</sup>	1582.00±85.28 <sup>Aa</sup>	906.00±107.73 <sup>Ba</sup>	1472.00±59.62 <sup>Aab</sup>
14	1035.00±53.51 <sup>BCa</sup>	1021.25±55.76 <sup>Cb</sup>	1533.50±88.05 <sup>Aa</sup>	1005.50±62.26 <sup>Ca</sup>	1491.00±52.06 <sup>Aab</sup>
21	1033.75±65.28 <sup>Ba</sup>	1000.00±64.77 <sup>Bb</sup>	1610.56±92.43 <sup>Aa</sup>	988.50±54.76 <sup>Ba</sup>	1506.00±50.23 <sup>Aab</sup>
28	1063.75±60.32 <sup>Ba</sup>	1095.00±95.08 <sup>Bb</sup>	1521.11±87.90 <sup>Aa</sup>	988.50±55.86 <sup>Ba</sup>	1525.00±50.82 <sup>Aab</sup>
35	1016.25±61.12 <sup>Ba</sup>	1105.71±106.14 <sup>Bb</sup>	1419.38±83.58 <sup>Aa</sup>	880.00±52.87 <sup>Ba</sup>	1537.00±49.58 <sup>Aab</sup>
40	1043.75±87.34 <sup>Ca</sup>	1385.71±105.53 <sup>Ba</sup>	1533.33±92.89 <sup>Aba</sup>	1045.00±50.03 <sup>Ca</sup>	1555.00±47.40 <sup>Aba</sup>

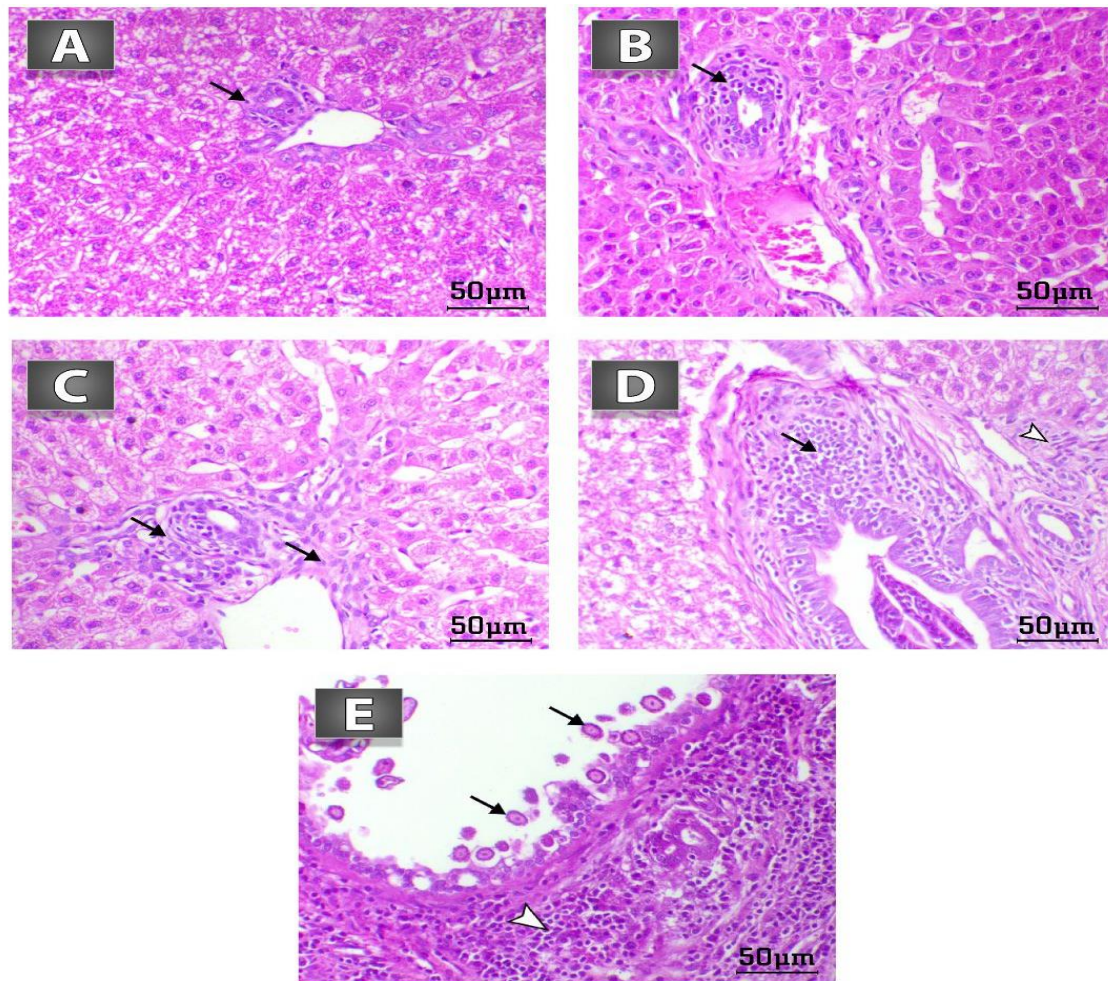
a, b and c: There is no significant difference ( $P>0.05$ ) between any two means, within the same column have the same superscript letter. A, B and C: There is no significant difference ( $P>0.05$ ) between any two means, within the same row same superscript letter. G1: *M. macroura* treated group, G2: *L. sativum* treated group, G3: Diclazuril group, G4: control positive (CP), G5: control negative (CN).

### Histopathological Findings and its Lesion Score

Upon comparing the histopathological changes of the livers of rabbits in G5 which showed normal histological pattern Fig. 2: A with the livers of different groups, we noticed that the livers in G1 treated with *M. macroura* showed decrease the intra-epithelial coccidian developmental stages and slight lymphohistiocytic inflammatory cells (B). The livers of rabbits in G2 treated with *L. sativum* showed marked decrease periportal fibrosis and mononuclear inflammatory cells infiltration (Fig. 2C). In G3 (Diclazuril group), livers showed a decrease in the coccidian developmental stages within the biliary epithelium, periductal fibrous connective tissue proliferation and marked

lymphohistiocytic inflammatory cells (D). Generally by the end of the experiment, the pathological changes recorded in the livers of all groups were significantly improved when compared with G4 (CP) which showed marked necrosis of the biliary epithelium accompanied with presence of numerous macro gametocytes of coccidian parasites and marked periductal lymphohistiocytic inflammatory cells infiltration (Fig. 2E).

Calculating the lesion score depending on the histopathological findings revealed that the biliary necrosis, hepatic necrosis, fibrosis, and extent of the lesions provoked in G4 (control positive) (3.67, 3.67, 3.33, 3.33) than the other groups. There was no significant difference between the G3 and G4 which showed the



**Fig. 2:** Histopathology of the liver of rabbits stained by H&E, bar=50µm in different experimental groups. **A):** control negative group, showed normal histological pattern. **B):** G1 treated with *M. macroura*, showed decrease the intra-epithelial coccidian developmental stages and slight lymphohistiocytic inflammatory cells (arrow). **C):** G2 treated with *L. sativum*, showed marked decrease periportal fibrosis and mononuclear inflammatory cells infiltration (arrows). **D):** G3 diclazuril group showed decrease the coccidian developmental stages within the biliary epithelium, periductal fibrous connective tissue proliferation (arrowhead) and marked lymphohistiocytic inflammatory cells (arrow). **E):** G4 control positive group, showed marked necrosis of the biliary epithelium accompanied with presence of numerous macro gametocytes of coccidial parasites (arrows) and marked periductal lymphohistiocytic inflammatory cells infiltration (arrowhead).

**Table 3:** Lesion score of histopathology of different groups

Lesion type	Groups				
	G1	G2	G3	G4	G5
Biliary necrosis	1.67±0.33 <sup>B</sup>	0.67±0.33 <sup>BC</sup>	1.67±0.33 <sup>B</sup>	3.67±0.33 <sup>A</sup>	0.00±0.00 <sup>C</sup>
Hepatic necrosis	1.67±0.33 <sup>B</sup>	1.33±0.33 <sup>B</sup>	1.67±0.33 <sup>B</sup>	3.67±0.33 <sup>A</sup>	0.00±0.00 <sup>C</sup>
Inflammation	1.67±0.33 <sup>B</sup>	1.33±0.33 <sup>B</sup>	2.33±0.33 <sup>AB</sup>	3.33±0.33 <sup>A</sup>	0.00±0.00 <sup>C</sup>
Fibrosis	1.33±0.33 <sup>B</sup>	1.00±0.58 <sup>BC</sup>	1.67±0.33 <sup>B</sup>	3.33±0.33 <sup>A</sup>	0.00±0.00 <sup>C</sup>
Extent of the lesions	1.33±0.33 <sup>B</sup>	0.67±0.33 <sup>BC</sup>	1.67±0.33 <sup>B</sup>	3.33±0.33 <sup>A</sup>	0.00±0.00 <sup>C</sup>

Values (Mean± SE) in the same row with different superscript Capital letters are significantly different at (P<0.05) between different groups. G1: *M. macroura* treated group, G2: *L. sativum* treated group, G3: Diclazuril group, G4: control positive (CP), G5: control negative (CN).

same degree of inflammation. In addition, there was no significant difference between G2 and G5 which showed the lowest degree of fibrosis and extent of the lesions. Here the result of the lesion score emphasized that all treated groups with botanicals extracts could decrease the pathological reaction following *E. stiedae* infection, as demonstrated in Table 3.

#### Biochemical and Hematological Parameters

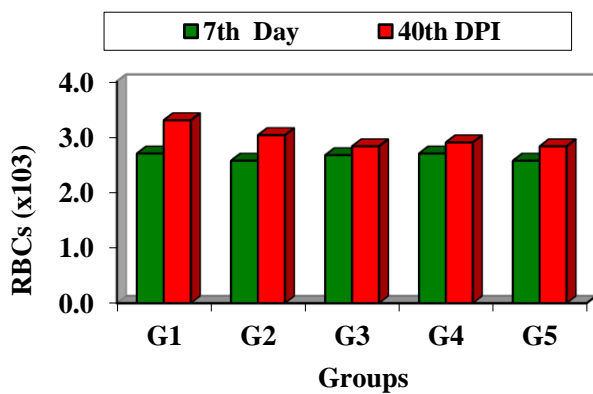
Concerning biochemical estimation of liver and kidney function in different groups on 40<sup>th</sup> DPI, no

significant difference (P>0.05) in creatinine levels was recorded between G2 (1.37), and G5 (1.20), but they were significantly lower than (P>0.05) that of G3 (1.83). Concerning urea level, no significant difference was recorded among different groups except Diclazuril group which showed an increase in urea level (68.93) compared to other groups. AST in all groups showed a significant decrease compared to G4 (27.67±1.76) except G2 which exhibited (22.00±1.00) no significant difference in comparison to G4. ALT level in all groups recorded a significant decrease compared to G4 (22.67) except G3

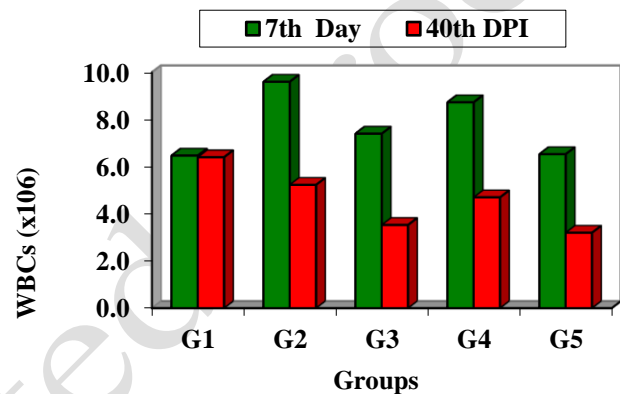
**Table 4:** Liver and kidney function tests of rabbits in different groups in 7<sup>th</sup> day (before infection) and day 40<sup>th</sup> DPI

	Days	Groups				
		G1	G2	G3	G4	G5
Creatinine	7 <sup>th</sup> Day	1.17±0.07 <sup>Bb</sup>	1.27±0.12 <sup>ABa</sup>	1.27±0.09 <sup>Abb</sup>	1.50±0.06 <sup>Aa</sup>	1.20±0.10 <sup>ABa</sup>
	40 DPI	1.57±0.12 <sup>ABa</sup>	1.37±0.09 <sup>BCa</sup>	1.83±0.09 <sup>Aa</sup>	1.53±0.12 <sup>ABa</sup>	1.20±0.12 <sup>Ca</sup>
Urea	7 <sup>th</sup> Day	33.77±0.47 <sup>Ab</sup>	38.40±5.81 <sup>Aa</sup>	40.70±1.65 <sup>Ab</sup>	43.93±2.03 <sup>Aa</sup>	35.17±2.54 <sup>Aa</sup>
	40 DPI	52.27±5.78 <sup>Ba</sup>	44.40±2.14 <sup>BCa</sup>	68.93±2.47 <sup>Aa</sup>	50.40±5.93 <sup>BCa</sup>	37.80±2.42 <sup>Ca</sup>
AST	7 <sup>th</sup> Day	14.33±0.88 <sup>Ba</sup>	14.00±1.15 <sup>Bb</sup>	13.00±0.00 <sup>BCb</sup>	17.67±0.67 <sup>Ab</sup>	12.00±0.58 <sup>BCb</sup>
	40 DPI	18.33±2.33 <sup>Ba</sup>	22.00±1.00 <sup>ABa</sup>	21.00±1.15 <sup>Ba</sup>	27.67±1.76 <sup>Aa</sup>	17.33±0.67 <sup>Ba</sup>
ALT	7 <sup>th</sup> Day	12.00±0.58 <sup>Ba</sup>	11.67±0.88 <sup>Bb</sup>	10.67±0.33 <sup>Bb</sup>	15.00±0.58 <sup>Ab</sup>	7.67±0.33 <sup>Cb</sup>
	40 DPI	17.00±2.00 <sup>Ba</sup>	17.33±0.33 <sup>Ba</sup>	18.33±1.45 <sup>ABa</sup>	22.67±1.86 <sup>Aa</sup>	13.33±0.33 <sup>Ba</sup>
GGT	7 <sup>th</sup> Day	13.67±1.76 <sup>ABa</sup>	13.00±0.58 <sup>ABb</sup>	12.33±0.88 <sup>ABb</sup>	16.00±1.15 <sup>Ab</sup>	11.67±0.88 <sup>Ba</sup>
	40 DPI	16.33±1.45 <sup>BCa</sup>	18.67±1.20 <sup>ABa</sup>	19.33±2.03 <sup>ABa</sup>	22.67±2.03 <sup>Aa</sup>	12.33±1.20 <sup>Ca</sup>
Albumin	7 <sup>th</sup> Day	3.50±0.00 <sup>Aa</sup>	3.40±0.06 <sup>ABa</sup>	3.30±0.00 <sup>Ba</sup>	3.47±0.09 <sup>Aa</sup>	3.27±0.03 <sup>Ba</sup>
	40 DPI	3.70±0.00 <sup>Aa</sup>	3.60±0.06 <sup>ABa</sup>	3.47±0.09 <sup>ABa</sup>	3.50±0.12 <sup>ABa</sup>	3.37±0.12 <sup>Ba</sup>

Values (Mean±SE) in the same raw with different superscript capital letters are significantly different at (P<0.05) between different groups at fixed time. While mean values in the same column with different superscript small letters are significantly different at (P<0.05) in different times within the same group. G1: *M. macroura* treated group, G2: *L. sativum* treated group, G3: Diclazuril group, G4: control positive (CP), G5: control negative (CN).



**Fig. 3:** Level of RBCs in different groups in 7<sup>th</sup> day (before infection) and the last day of the experiment (40<sup>th</sup> DPI). G1: *M. macroura* treated group, G2: *L. sativum* treated group, G3: Diclazuril group, G4: control positive (CP), G5: control negative (CN).



**Fig. 4:** Level of WBCs in different groups in 7<sup>th</sup> day (before infection) and the last day of the experiment (40<sup>th</sup> DPI). G1: *M. macroura* treated group, G2: *L. sativum* treated group, G3: Diclazuril group, G4: control positive (CP), G5: control negative (CN).

**Table 5:** Hematological parameters in different groups in 7<sup>th</sup> day (before infection) and the last day of the experiment (40<sup>th</sup> DPI)

Hematological parameters	Days	Groups				
		G1	G2	G3	G4	G5
RBCs	7 <sup>th</sup> Day	2.70±0.10 <sup>Ab</sup>	2.57±0.03 <sup>Aa</sup>	2.67±0.03 <sup>Aa</sup>	2.70±0.10 <sup>Aa</sup>	2.57±0.03 <sup>Aa</sup>
	40 <sup>th</sup> DPI	3.30±0.10 <sup>Aa</sup>	3.03±0.23 <sup>Aa</sup>	2.83±0.17 <sup>Aa</sup>	2.90±0.25 <sup>Aa</sup>	2.83±0.17 <sup>Aa</sup>
HB	7 <sup>th</sup> Day	7.90±0.25 <sup>Ab</sup>	7.57±0.13 <sup>Aa</sup>	7.87±0.13 <sup>Aa</sup>	7.90±0.25 <sup>Aa</sup>	7.80±0.36 <sup>Aa</sup>
	40 <sup>th</sup> DPI	9.63±0.27 <sup>ABa</sup>	8.90±0.64 <sup>ABCa</sup>	8.30±0.50 <sup>BCa</sup>	7.93±0.45 <sup>BCa</sup>	8.43±0.26 <sup>BCa</sup>
PCV	7 <sup>th</sup> Day	22.80±0.71 <sup>Ab</sup>	21.67±0.33 <sup>Aa</sup>	22.83±0.47 <sup>Aa</sup>	22.80±0.71 <sup>Aa</sup>	21.67±0.33 <sup>Aa</sup>
	40 <sup>th</sup> DPI	27.80±0.80 <sup>ABa</sup>	25.80±1.85 <sup>ABCa</sup>	24.00±1.40 <sup>BCa</sup>	25.37±1.64 <sup>ABCa</sup>	24.13±0.94 <sup>BCa</sup>
MCV	7 <sup>th</sup> Day	81.30±3.50 <sup>Aa</sup>	85.43±0.58 <sup>Aa</sup>	82.27±3.93 <sup>Aa</sup>	81.17±3.42 <sup>Aa</sup>	86.07±0.13 <sup>Aa</sup>
	40 <sup>th</sup> DPI	84.53±0.43 <sup>Aa</sup>	85.10±0.51 <sup>Aa</sup>	84.07±0.47 <sup>Aa</sup>	84.67±0.78 <sup>Aa</sup>	85.17±0.44 <sup>Aa</sup>
MCH	7 <sup>th</sup> Day	27.63±1.63 <sup>Aa</sup>	29.47±0.13 <sup>Aa</sup>	28.07±1.83 <sup>Aa</sup>	27.63±1.63 <sup>Aa</sup>	27.50±1.55 <sup>Aa</sup>
	40 <sup>th</sup> DPI	29.17±0.07 <sup>Aa</sup>	29.33±0.15 <sup>Aa</sup>	29.23±0.33 <sup>Aa</sup>	29.30±0.31 <sup>Aa</sup>	29.37±0.27 <sup>Aa</sup>
MCHC	7 <sup>th</sup> Day	32.87±1.73 <sup>Aa</sup>	34.60±0.00 <sup>Aa</sup>	32.87±1.73 <sup>Aa</sup>	32.87±1.73 <sup>Aa</sup>	34.60±0.00 <sup>Aa</sup>
	40 <sup>th</sup> DPI	34.60±0.00 <sup>Aa</sup>	34.60±0.00 <sup>Aa</sup>	34.60±0.00 <sup>Aa</sup>	34.60±0.00 <sup>Aa</sup>	34.60±0.00 <sup>Aa</sup>
WBCs	7 <sup>th</sup> Day	6.47±1.19 <sup>Aa</sup>	9.60±2.53 <sup>Aa</sup>	7.40±1.25 <sup>Aa</sup>	8.73±1.47 <sup>Aa</sup>	6.53±0.87 <sup>Aa</sup>
	40 <sup>th</sup> DPI	6.40±1.51 <sup>ABa</sup>	5.23±0.55 <sup>BCa</sup>	3.53±0.30 <sup>Cb</sup>	4.70±0.46 <sup>BCa</sup>	3.20±0.10 <sup>Cb</sup>
Platelets	7 <sup>th</sup> Day	393.33±38.44 <sup>Aa</sup>	311.67±41.47 <sup>ABa</sup>	356.67±67.15 <sup>ABa</sup>	309.33±46.86 <sup>ABa</sup>	358.33±65.21 <sup>ABa</sup>
	40 <sup>th</sup> DPI	283.33±19.65 <sup>Aa</sup>	277.33±54.03 <sup>Aa</sup>	299.67±15.39 <sup>Aa</sup>	164.33±3.53 <sup>Bb</sup>	288.00±4.36 <sup>Aa</sup>

Values (Mean±SE) in the same raw with different superscript capital letters are significantly different at (P<0.05) between different groups at fixed time. While mean values in the same column with different superscript small letters are significantly different at (P<0.05) in different times within the same group. G1: *M. macroura* treated group, G2: *L. sativum* treated group, G3: Diclazuril group, G4: control positive (CP), G5: control negative (CN).

which revealed no significant change (18.33) when compared to G4. GGT level showed a significant decrease in G1 (16.33), and G5 (12.33) compared to G4 (22.67), as described in Table 4.

Regarding hematological parameters, on the 7<sup>th</sup> day, there is no change in hematological parameters among all groups while on day 40<sup>th</sup> DPI there is no significant difference (P<0.05) in RBCs, Hb, PCV, MCV, MCH, and

**Table 6:** Differential leukocyte count of rabbits in different groups in 7<sup>th</sup> day (before infection) and last day of the experiment 40<sup>th</sup> DPI

Leukocyte type	Day	Groups				
		G1	G2	G3	G4	G5
Neutrophil	7 <sup>th</sup> Day	15.00±1.15 <sup>Aa</sup>	15.67±1.45 <sup>Aa</sup>	14.67±0.88 <sup>Aa</sup>	15.33±1.20 <sup>Aa</sup>	14.67±0.88 <sup>Aa</sup>
	40 <sup>th</sup> DPI	8.33±0.88 <sup>Ab</sup>	9.00±1.15 <sup>Ab</sup>	11.00±1.15 <sup>Aa</sup>	11.33±1.76 <sup>Aa</sup>	7.33±0.88 <sup>Bb</sup>
Lymphocytes	7 <sup>th</sup> Day	76.00±1.53 <sup>Ab</sup>	77.67±1.45 <sup>Ab</sup>	78.00±0.58 <sup>Aa</sup>	76.33±2.03 <sup>Aa</sup>	73.33±0.33 <sup>ABb</sup>
	40 <sup>th</sup> DPI	87.00±0.58 <sup>ABa</sup>	85.67±1.86 <sup>ABa</sup>	83.67±2.03 <sup>Ba</sup>	82.33±2.33 <sup>Ba</sup>	81.00±1.53 <sup>Ca</sup>
Monocytes	7 <sup>th</sup> Day	6.00±0.58 <sup>Aa</sup>	5.67±0.33 <sup>Aa</sup>	6.00±0.58 <sup>Aa</sup>	5.33±0.33 <sup>Aa</sup>	6.00±0.58 <sup>Aa</sup>
	40 <sup>th</sup> DPI	3.33±0.33 <sup>Ab</sup>	3.67±0.33 <sup>Ab</sup>	4.33±0.33 <sup>Aa</sup>	3.67±0.33 <sup>Ab</sup>	2.67±0.33 <sup>Bb</sup>
Eosinophils	7 <sup>th</sup> Day	1.67±0.33 <sup>Ba</sup>	1.00±0.00 <sup>Ba</sup>	1.00±0.00 <sup>Ba</sup>	2.00±0.58 <sup>Ba</sup>	1.33±0.33 <sup>Ba</sup>
	40 <sup>th</sup> DPI	1.33±0.67 <sup>ABa</sup>	1.00±0.00 <sup>ABa</sup>	1.00±0.58 <sup>ABa</sup>	2.33±0.33 <sup>Aa</sup>	0.33±0.33 <sup>Ba</sup>
Basophiles	7 <sup>th</sup> Day	1.33±0.33 <sup>Aa</sup>	0.00±0.00 <sup>Aa</sup>	0.33±0.33 <sup>Aa</sup>	1.00±0.58 <sup>Aa</sup>	0.33±0.33 <sup>Aa</sup>
	40 <sup>th</sup> DPI	0.00±0.00 <sup>Bb</sup>	0.00±0.00 <sup>Ba</sup>	0.00±0.00 <sup>Ba</sup>	1.33±0.33 <sup>Aa</sup>	0.00±0.00 <sup>Ba</sup>

Values (Mean±SE) in the same row with different superscript capital letters are significantly different at ( $P < 0.05$ ) between different groups at fixed time. While mean values in the same column with different superscript small letters are significantly different at ( $P < 0.05$ ) in different times within the same group. G1: *M. macroura* treated group, G2: *L. sativum* treated group, G3: Diclazuril group, G4: control positive (CP), G5: control negative (CN).

MCHC among all groups except G4 which recorded a significant ( $P < 0.05$ ) decrease in platelets count (164.33) compared to other groups. There is an improvement in the level of RBCs (Fig.3), Hb, and PCV in (G1) on day 40<sup>th</sup> DPI compared to the 7<sup>th</sup> day. On the other hand, G1 showed significant increase in level of WBCS compared to (G3, G5) (Fig. 4; Table 5).

Differential leukocyte counts were without significant difference in all groups on the 7<sup>th</sup> day. On the 40<sup>th</sup> DPI, group (5) showed a significant decrease in neutrophils (7.33), lymphocytes (81), and monocyte (2.67) compared to other groups while the level of eosinophils (33) showed a significant decrease compared to G2 (1), and G4 (2.3). Group (4) recorded the highest level of Basophils (1.33) compared to other groups, as observed in Table 6.

## DISCUSSION

Searching for new anti-coccidial, such as the use of natural additives, has emerged as an alternative method of controlling coccidiosis. Previous research had demonstrated that antioxidant-rich plant extracts had pledge anti-coccidial potential and can be used as effective substitutes for synthetic anti-coccidial drugs (Fall et al. 2016; Abu El Ezz et al. 2020; Qureshi 2021; Han et al. 2022). Furthermore, when compared to synthetic chemical drugs, these extracts are natural, cheaper, and more enticing, with no residual effect (Pérez-Fonseca et al. 2016; Abbas et al. 2017). In the present study, the use of *M. macroura* and *L. sativum* for the treatment of *E. stiedae* in experimentally infected rabbits declared that the botanical extracts have a strong anti-coccidial effect and improve weight gain.

Although the parasite was not totally suppressed in any of the infected treatment groups, minimal clinical symptoms appeared throughout the experiment. It was noted that plant extracts significantly reduced mortality rate, drop in oocysts output, and lesion count. Regarding the oocysts count of *E. stiedae* among infected rabbits *M. macroura* gave good result as an anti-coccidial plant. *M. macroura* displayed a significant oocysts reduction ( $P > 0.05$ ) from 17<sup>th</sup> to 32<sup>nd</sup> DPI in comparison to G4 (control positive group) with superiority to *M. macroura* group on days 28<sup>th</sup>, 29<sup>th</sup>, 30<sup>th</sup>, and 32<sup>nd</sup> which displayed a significant oocysts reduction ( $P > 0.05$ ) in comparison to

G3 (Diclazuril group) and showed the lowest level of oocysts shedding from 23<sup>rd</sup>- 27<sup>th</sup> DPI compared to G2 (*L. sativum* group).

Such effect may attributed to *M. macroura*'s bioactive components such as flavonoids and phenolic acids, which were previously shown to have an assortment of beneficial therapeutic effects (Nile and Park 2014; Skrovankova et al. 2015; El-Haddad et al. 2021; Memete et al. 2022). These dietary polyphenolic compounds have been proven to have antioxidant and anti-inflammatory activity. *M. macroura* has not previously been used against *E. stiedae* or coccidiosis but has proven to be effective in treating many diseases, including peptic ulcer and inflammatory bowel disease (Farzaei et al. 2015). Furthermore, Salama et al. (2020) illustrated that a beneficial therapeutic effect of *M. macroura* against AA-induced ulcerative colitis through the inhibition of the inflammatory response. So anti-coccidial effect against *E. stiedae* may be due to its bioactive ingredients, which caused a reduction in oocysts shedding, improve the general health condition of rabbits, and body weight gain.

Also *L. sativum* displayed a significant oocysts reduction ( $P > 0.05$ ) from the 17<sup>th</sup> to 32<sup>nd</sup> DPI in comparison to G4 (control group) with superiority to *L. sativum* on 17<sup>th</sup>, 19<sup>th</sup>, 20<sup>th</sup>, 22<sup>nd</sup>, 28<sup>th</sup>, 29<sup>th</sup>, 30<sup>th</sup>, and 31<sup>st</sup> DPI compared to G1, and G3 and improve in body weight gain, especially at 40<sup>th</sup> DPI of the experiment, this is in adherence with the findings of Adamu and Boonkaewwan (2014) who observed that broiler chicken after being infected with *E. tenella*, chickens fed a diet rich in *Lepidium sativum* showed a significantly lower drop in mortality, faecal oocyst shed, and lesion score which proved good protective effects of *L. sativum*.

To our knowledge, this is the first study record on studying the protective effects of *L. sativum* against *E. stiedae*. Protective effects of *L. sativum* treated group might be linked with anti-inflammatory, antioxidant, immunomodulatory and hepatoprotective properties of *L. sativum* due to its phenolic compounds, antioxidants, and high n-3 fatty acids (Vazifeh et al. 2022; Painuli et al. 2022).

According to Naidoo et al. (2008) and Adamu and Boonkaewwan (2014), it has also been reported that antioxidant-rich plant extracts and n-3 fatty acids may help in treating cecal coccidiosis infections in chickens by inhibiting *E. tenella* intracellular development or boosting host immunity (Delaquis et al. 2002).

PM lesion and histopathological changes of the liver of sacrificed rabbit in G4 (CP) were consistent with the previous research (Al-Naimi et al. 2012; Kardena et al. 2015; Harcourt-Brown et al. 2020; Metwally et al. 2022). These lesions may be caused by the released toxins by *Eimeria stiedae* or mechanical irritation or due to lipid peroxidation produced by *E. stiedae*, resulting in the destruction of the bile ducts and consequently hepatic parenchyma. Conversely, the rabbits in *M. macroura* and *L. sativum* (G1 and G2) had almost a normal liver at PM inspection and the microscopical architecture of the liver indicating its protective effect against *E. stiedae* infection which coincided with the results previously recorded by Kardena et al. (2015). Moreover, it was noticed that the liver lesions were completely ameliorated by diclazuril where the liver showed no visible lesions related to hepatic coccidiosis although marked decrease in periportal fibrosis and mononuclear inflammatory cells infiltration and gall bladder showing mild epithelial hyperplasia which may be recovered by time as suggested by Seddiek and Metwally (2013).

Upon studying the lesion score of histopathology, the livers of rabbits in G2 showed the lowest score in the degree of fibrosis, extent of the lesions and they were significantly consistent with that of G5 (CN). This improvement can ensure the effective action of *L. sativum* in preventing coccidial intracellular development (Delaquis et al. 2002).

Generally, coccidiosis causes a change in biochemical and blood parameters. It was observed that, at the end of the experiment a significant decrease in creatinine was recorded in G2 compared to G3 while the diclazuril group (G3) had higher urea levels than the other groups which was attributed to a disturbance with the urea cycle in the liver (Yaplito-Lee et al. 2013). Besides, the reduction in serum level of (ALT, AST, and GGT) in botanically treated groups and diclazuril group when compared to CP group. The increase in serum enzymatic activity in CP may be related to cell destruction induced by the parasitic infection, which caused the escape of enzymes into the bloodstream (Hanada et al. 2003), especially high levels of GGT and AST might be a sign of the broken epithelial covering of the bile channel due to increased numbers of parasite oocysts (Sanyal and Sharma 1990). While the improvement in blood serum enzymes in the treated groups can be attributed to the repair of hepatic cells and epithelial lining, as well as the restriction of parasite sexual stage development.

Following treatment, the recovery included healing of damaged liver tissues and bile ducts (the primary site of infection) as well as normalization of many biochemical parameter levels, including liver enzymes and blood serum proteins following treatment. These results are similar to the findings of Abdel Maged et al. (2013) and Çam et al. (2008). In addition, Faris et al. (2011) who documented that coccidiosis in kids caused a substantial increase in serum AST, ALT, urea, and creatinine while the current findings demonstrated that after treatment with herbal extracts, all biochemical parameters examined were restored to normal levels, confirming their anti-coccidial efficacy and hepatoprotective actions.

All groups had similar levels of RBCs, Hb, PCV, MCV, MCH, and MCHC except G4 (control positive) which showed the lowest level of platelets count compared to other groups. Moreover, there was an improvement in the level of RBCs, Hb, and PCV in (G1) on day 40<sup>th</sup> DPI compared to the 7<sup>th</sup> day, this proved that herbal extracts caused improved general health of rabbits when their parameters compared to their pre-experiment values.

There was virtually no variation between the groups in different leukocytic counts in our study and this is explained by Castro and Duszynski (1984) who reported that rats infected with *E. nieschulzi* interferes with some phases in the directed migration of leukocytes to sites of inflammation and does not affect hematopoiesis that is the reason why the granulocyte count (lymphocytes and monocytes) in peripheral blood is normal or slightly increased in coccidial rabbits in our study.

The outcomes in our finding revealed significant increase in level of neutrophil in all groups compared to CN group and this studied with the earlier reports, which ascribed these effects to an inflammatory response to infection (Çam et al. 2008) which suggested that neutrophilia is pathologically induced by infections but also might be a possible marker of the stress response because of the endogenous release of corticosteroids, which have a crucial function in regulating the circulating concentration of leukocytes (Zahorec 2001; Merlot 2004). There was increase in level of eosinophils in G2 and G4 compared to G5, although eosinophilia in rabbits rarely occurs but it may be associated with parasitism eosinophilia which occurs as a pathophysiological response to infection with parasites through participation in the immune response by discharging their cytotoxic granular contents (Capron 1991; Rothenberg 1998).

## Conclusion

To our knowledge, this study was the first to inspect the protective effect of *M. macroura* and *L. sativum* supplementation against experimentally induced coccidian infection in rabbits. We concluded that oral administration of *M. macroura* and *L. sativum* can be used safely and effectively against *E. stiedae* in rabbits with no side effects except the presence of slight hyperplasia in the epithelial cells of the gall bladder that may be recovered over time. In addition to, improvement of growth performance as well as liver and kidney functions and give protection comparable to that exhibited by diclazuril. Future pharmacological studies are needed to know the exact mode of action of the used plants.

## Author Contributions

All authors contributed to conceptualization, methodology, investigation, resources, and editing supervision. Writing original draft. All authors have read and agreed to the published version of the manuscript.

## Acknowledgments

We acknowledge many thanks to Dr. Najwa El-Hawary for contributing to the *E. stiedae* strain.

## Conflicts of Interest

The authors declare no conflict of interest.



## REFERENCES

- Abbas A, Abbas RZ, Khan MK, Raza MA, Mahmood MS, Saleemi MK, Hussain T, Khan JA and Sindhu ZUD, 2019. Anticoccidial effects of *Trachyspermum ammi* (Ajwain) in broiler chickens. *Pakistan Veterinary Journal* 39(2): 301–304. <https://doi.org/10.29261/pakvetj/2019.056>
- Abbas A, Iqbal Z, Abbas RZ, Khan MK, Khan JA, Sindhu ZUD, Mahmood MS and Saleemi MK, 2017. In vivo anticoccidial effects of *Beta vulgaris* (sugar beet) in broiler chickens. *Microbial Pathogenesis* 111: 139-144. <https://doi.org/10.1016/j.micpath.2017.07.052>
- Abdel Maged A, Ahmed NE, Ramadan MY and Elashrey MA, 2013. Biochemical effects of antiprotozoa on gastrointestinal tract enzymes and related hormones in rabbits. *Benha Veterinary Medical Journal* 25(2): 113–124.
- Abdel Megeed K, Abuel Ezz N and Abdel-Rahman EH, 2005. Protective effect of *Eimeria stiedae* coproantigen against hepatic coccidiosis in rabbits. *Journal of the Egyptian Society of Parasitology* 35(2): 581–595.
- Aboelhadid SM, El-Ashram S, Hassan KM, Arafa WM and Darwish AB, 2019. Hepato- protective effect of curcumin and silymarin against *Eimeria stiedae* in experimentally infected rabbits. *Livestock Science* 221: 33–38. <https://doi.org/10.1016/j.livsci.2019.01.011>
- AbouLaila M, Zaid A, Roshdey T, Allam T and Elkhatam A, 2020. *Eimeria stiedae*: Infection rate and molecular characterization by nested PCR in rabbits from Minoufiya Governorate, Egypt. *Egyptian Veterinary Medical Society of Parasitology Journal* 16: 34-49. [10.21608/EVMSPI.2020.96759](https://doi.org/10.21608/EVMSPI.2020.96759)
- Abu El Ezz NMT, Aboelsoued D, Hassan SE, Abdel Megeed KN and El-Metenawy TM, 2020. Therapeutic effect of *Moringa oleifera* and *Thymus vulgaris* oils against hepatic coccidiosis in experimentally infected rabbits. *Tropical Biomedicine* 37(4): 1018–1028.
- Adamu M and Boonkaewwan C, 2014. Effect of *Lepidium sativum* L.(garden cress) seed and its extract on experimental *Eimeria tenella* infection in broiler chickens. *Agriculture and Natural Resources* 48(1): 28–37.
- Al-Naimi RAS, Khalaf OH, Tano SY and Al-Taei EH, 2012. Pathological study of hepatic coccidiosis in naturally infected rabbits. *Al-Qadisiyah Journal of Veterinary Medicine Sciences* 11(1): 63–69. <https://doi.org/10.29079/voll1iss1art172>
- Al-Rukibat RK., Irizarry AR., Lacey JK., Kazacos KR, Storandt ST and DeNicola DB, 2001. Impression smear of liver tissue from a rabbit. *Veterinary Clinical Pathology* 30(2): 57– 61. <https://doi.org/10.1111/j.1939-165X.2001.tb00259.x>
- Bochyńska D , Lloyd S, Restif O and Hughes K, 2022. *Eimeria stiedae* causes most of the white-spotted liver lesions in wild European rabbits in Cambridgeshire, United Kingdom. *Journal of Veterinary Diagnostic Investigation* 34(2): 199-205. <https://doi.org/10.1177/10406387211066923>
- Çam Y, Atasever A, Eraslan G, Kibar M, Atalay Ö, Beyaz L, İnci A and Liman BC. 2008. *Eimeria stiedae*: experimental infection in rabbits and the effect of treatment with toltrazuril and ivermectin. *Experimental Parasitology* 119(1): 164–172. <https://doi.org/10.1016/j.exppara.2008.01.005>
- Capron M, 1991. Eosinophils and parasites. *Annales de Parasitologie Humaine et Comparée* 66: 41–45.
- Castro GA and Duszynski DW, 1984. Local and Systemic Effects on Inflammation during *Eimeria nieschulzi* Infection 1: Anti-Inflammation In *E. Nieschulzi* Infection. *The Journal of Protozoology* 31(2): 283–287. <https://doi.org/10.1111/j.1550-7408.1984.tb02962.x>
- Culling C, 1983. *Hand book of Histological and Histochemical Techniques*. 3rd Ed. Butterworth.
- Dalloul RA and Lillehoj HS, 2006. Poultry coccidiosis: recent advancements in control measures and vaccine development. *Expert Review of Vaccines* 5(1): 143–163. <https://doi.org/10.1586/14760584.5.1.143>
- Delacuis PJ, Stanich K, Girard B and Mazza G, 2002. Antimicrobial activity of individual and mixed fractions of dill, cilantro, coriander and eucalyptus essential oils. *International Journal of Food Microbiology* 74(1–2): 101–109. <https://doi.org/10.1586/14760584.5.1.143>
- El-Akabawy, L M, Zayan KA, Tantawy A A and Omar R E M, 2004. Anticoccidial efficacy of propolis and toltrazuril against *Eimeria stiedae* in New Zealand white rabbit's. *Zagazig Veterinary Journal* 32(1): 129–145.
- El-Haddad A, El-Deeb EM, Amer AA, Saadeldeen AM, Ahmed FM, Salem MA and Taha HS, 2021. Bioactive phytoconstituents of morus plants exhibiting numerous therapeutic activities. *Egyptian Journal of Chemistry* 64(9): 5299-5313.
- El-Ghany WAA, 2021. Intervention strategies for controlling poultry coccidiosis: current knowledge. *Journal of World's Poultry Research* 11(4): 487–505. <https://dx.doi.org/10.36380/jwpr.2021.58>
- El-Shahawi GA, El-Fayomi HM and Abdel-Haleem HM, 2012. Coccidiosis of domestic rabbit (*Oryctolagus cuniculus*) in Egypt: light microscopic study. *Parasitology Research* 110(1): 251–258. <https://doi.org/10.1007/s00436-011-2479-0>
- Fall AD, Gbati OB, Diatta W, Lapo RA, Diatta-Badji K, Dieng M, Dieng SIM, Bassene E and Pangui LJ, 2016. Anticoccidial activity of ethanol roots extract of *Cassia sieberiana* DC in chickens. *European Journal of Medicinal Plants* 11(1): 1-7. <https://doi.org/10.9734/EJMP/2016/21343>
- Faris AE, Ahmed EA, Shawky NA and Mahmoud FA, 2011. Field trial for treatment of coccidiosis in goat kids in Sharkia Governorate. *Zagazig Veterinary Journal* 39(1): 136–143.
- Farzaei H M, Rahimi R and Abdollahi M, 2015. The role of dietary polyphenols in the management of inflammatory bowel disease. *Current Pharmaceutical Biotechnology* 16(3): 196–210. <https://doi.org/10.2174/1389201016666150118131704>
- Farzaei MH, Abdollahi M and Rahimi R, 2015. Role of dietary polyphenols in the management of peptic ulcer. *World Journal of Gastroenterology* 21(21): 6499. <https://doi.org/10.3748/wjg.v21.i21.6499>
- Hamdan DI, Salah S, Hassan WHB, Morsi M, Khalil HMA, Ahmed-Farid OA, El-Shiekh RA, Nael MA and Elissawy AM, 2022. Anticancer and Neuroprotective Activities of Ethyl Acetate Fractions from *Morus macroura* Miq. *Plant Organs with Ultraperformance Liquid Chromatography-Electrospray Ionization-Tandem Mass Spectrometry Profiling*. *ACS Omega* 7(18): 16013-16027. <https://doi.org/10.1021/acsomega.2c01148.569>
- Han M, Hu W, Chen T, Guo H, Zhu J and Chen F, 2022. Anticoccidial activity of natural plants extracts mixture against *Eimeria tenella*: An in vitro and in vivo study. *Frontiers in Veterinary Science* 9: 1066543. <https://doi.org/10.3389/fvets.2022.1066543>
- Hanada S, Omata Y, Umamoto Y, Kobayashi Y, Furuoka H, Matsui T, Maeda R and Saito A, 2003. Relationship between liver disorders and protection against *Eimeria stiedae* infection in rabbits immunized with soluble antigens from the bile of infected rabbits. *Veterinary Parasitology* 111(2–3): 261–266. [https://doi.org/10.1016/S0304-4017\(02\)00357-6.574](https://doi.org/10.1016/S0304-4017(02)00357-6.574)
- Harcourt-Brown N, Silkstone M, Whitbread TJ and Harcourt-Brown FM, 2020. RHDV2 epidemic in UK pet rabbits. Part 1: Clinical features, gross post mortem and

- histopathological findings. *Journal of Small Animal Practice* 61(7): 419–427. <https://doi.org/10.1111/jsap.13141578>
- Hassan KM, Arafa WM, Mousa WM, Shokier KAM, Shany SA and Aboelhadid SM, 2016. Molecular diagnosis of *Eimeria stiedae* in hepatic tissue of experimentally infected rabbits. *Experimental Parasitology* 169: 1–5. <https://doi.org/10.1016/j.exppara.2016.07.001>
- Kadykalo S, Roberts T, Thompson M, Wilson J, Lang M and Espeisse O, 2018. The value of anticoccidials for sustainable global poultry production. *International Journal of Antimicrobial Agents* 51(3): 304–310. <https://doi.org/10.1016/j.ijantimicag.2017.09.004>
- Karaer Z, 2001. Evcil Tavsanlarda (*Oryctolagus cuniculus*) Coccidiosis. *Coccidiosis (Türkiye Parazitoloji Dernegi Yayin. Bornova-İzmir* 17: 269-278.
- Kardena IM, Ketut B, Ida B, Oka W, Ida B, Made O and Siswanto FM, 2015. Pathological case study of rabbit hepatic coccidiosis in tabanan, Bali. *Proceeding-Kuala Lumpur International Agriculture, Forestry and Plantation*.
- Khater HF, Ziam H, Abbas A, Abbas RZ, Raza MA, Hussain K, Younis EZ, Radwan IT and Selim A, 2020. Avian coccidiosis: Recent advances in alternative control strategies and vaccine development. *Agrobiological Records* 1: 11-25. <https://doi.org/10.47278/journal.abr/2020.003>
- Levine ND, 1985. *Veterinary Protozoology*, Iowa State Univ. Press Ames Iowa.
- Long PL, Millard BJ, Joyner LP and Norton CC, 1976. A guide to laboratory techniques used in the study and diagnosis of avian coccidiosis. *Folia Veterinaria Latina* 6(3): 201–217.
- Memete AR, Timar AV, Vuscan AN, Groza FM, Venter AC and Vicas SI, 2022. Phytochemical composition of different botanical parts of *Morus* species, health benefits and application in food industry. *Plants* 11: 152. <https://doi.org/10.3390/plants11020152>
- Merlot E, 2004. Conséquences du stress sur la fonction immunitaire chez les animaux d'élevage. *Productions Animales* 17(4): 255–264.
- Metwally DM, Alkharji AF, Barakat IAH, Baghdadi HB, El-Khadragy MF, Al-Megrin WAI, Alanazi AD and Alajmi FE, 2022. Protective effect of litchi chinensis peel extract-prepared nanoparticles on rabbits experimentally infected with *Eimeria stiedae*. *Animals* 12(22): 3098. <https://doi.org/10.3390/ani12223098606>
- Naidoo V, McGaw LJ, Bisschop SPR, Duncan N and Eloff JN, 2008. The value of plant extracts with antioxidant activity in attenuating coccidiosis in broiler chickens. *Veterinary Parasitology* 153(3–4): 214–219. <https://doi.org/10.1016/j.vetpar.2008.02.013>
- Nile SH and Park SW, 2014. Edible berries: Bioactive components and their effect on human health. *Nutrition* 30(2): 134–144. <https://doi.org/10.1016/j.nut.2013.04.007613>
- Painuli S, Quispe C, Herrera-Bravo J, Semwal P, Martorell M, Almarhoon ZM, Seilkhan A, Ydyrys A, Rad JS, Alshehri MM, Daştan SD, Taheri Y, Calina D and Cho WC, 2022. Nutraceutical profiling, bioactive composition, and biological applications of *Lepidium sativum* L. *Oxidative Medicine and Cellular Longevity* 2022: 291041. <https://doi.org/10.1155/2022/2910411>
- Pérez-Fonseca A, Alcalá-Canto Y, Salem AZM and Alberti-Navarro AB, 2016. Anticoccidial efficacy of naringenin and a grapefruit peel extract in growing lambs naturally-infected with *Eimeria* spp. *Veterinary Parasitology* 232: 58–65. <https://doi.org/10.1016/j.vetpar.2016.11.009>
- Qureshi NA, 2021. In vitro anticoccidial, antioxidant activities and biochemical screening of methanolic and aqueous leaves extracts of selected plants. *Pakistan Veterinary Journal* 41(1): 57-63. <https://doi.org/10.29261/pakvetj/2020.071>
- Rabie SAH, Abuelwafa WA and Hussein NM, 2022. Occurrence of *Eimeria* species (Apicomplexa: Eimeriidae) in domestic rabbits (*Oryctolagus cuniculus*) in Qena Governorate, Upper Egypt. *Journal of Parasitic Diseases* 46(3): 811-832. <https://doi.org/10.1007/s12639-022-01494-2>
- Rothenberg ME, 1998. Eosinophilia. *New England Journal of Medicine* 338(22): 1592–1600. <https://doi.org/10.1056/NEJM199805283382206>
- Salama RM, Darwish SF, El Shaffei I, Elmongy NF, Afifi MS and Abdel-Latif GA, 2020. *Morus macroura* Miq. Fruit extract protects against acetic acid-induced ulcerative colitis in rats: Novel mechanistic insights on its impact on miRNA-223 and on the TNF $\alpha$ /NF $\kappa$ B/NLRP3 inflammatory axis. *Food and Chemical Toxicology* 165: 113146. <https://doi.org/10.1016/j.fct.2022.113146>
- Sanyal PK and Sharma SC, 1990. Clinicopathology of hepatic coccidiosis in rabbits. *Indian Journal of Animal Sciences* 60(8): 924–928.
- Seddiek AS and Metwally MA, 2013. Anticoccidial activity of black cumin (*Nigella sativa*) in rabbits. *Assiut Veterinary Medical Journal* 59(138): 85–96. <https://doi.org/10.21608/AVMJ.2013.171808>
- Skrovankova S, Sumczynski D, Mlcek J, Jurikova T and Sochor J, 2015. Bioactive compounds and antioxidant activity in different types of berries. *International Journal of Molecular Sciences* 16(10): 24673–24706. <https://doi.org/10.3390/ijms161024673>
- Steel R and Torrie JDD, 1997. *Principles and Procedures of Statistics: A Biometrical Approach*. 3rd Ed. McGraw-Hill.
- Teklehaymanot T, Giday M, Medhin G and Mekonnen Y, 2007. Knowledge and use of medicinal plants by people around Debre Libanos monastery in Ethiopia. *Journal of Ethnopharmacology* 111(2): 271–283. <https://doi.org/10.1016/j.jep.2006.11.019>
- Tewari AK and Maharana B, 2011. Control of poultry coccidiosis: changing trends. *Journal of Parasitic Diseases* 35(1): 10–17. <https://doi.org/10.1007/s12639-011-0034-7>
- Tirtha SS, 2005. *The Ayurveda Encyclopedia*, edited by RC Uniyal. Ayurveda Holistic Center Press, USA, 360.
- Vanparijs O, Marsboom R and Desplenter L, 1989. Diclazuril, a new broad spectrum anticoccidial drug in chickens.: 1. dose titration studies and pilot floor pen trials. *Poultry Science* 68(4): 489–495. <https://doi.org/10.3382/ps.0680489>
- Vazifeh S, Kananpour P, Khalilpour M, Eaisalou SV and Hamblin MR, 2022. Anti-inflammatory and immunomodulatory properties of *Lepidium sativum*. *BioMed Research International* 2022: 3645038. <https://doi.org/10.1155/2022/3645038>
- Yaplito-Lee J, Chow CW and Boneh A, 2013. Histopathological findings in livers of patients with urea cycle disorders. *Molecular Genetics and Metabolism* 108(3): 161–165. <https://doi.org/10.1016/j.ymgme.2013.01.006>
- Zahorec R, 2001. Ratio of neutrophil to lymphocyte counts-rapid and simple parameter of systemic inflammation and stress in critically ill. *Bratislavske Lekarske Listy* 102(1): 5–14.
- Zia-Ul-Haq M, Ahmad S, Calani L, Mazze T, Rio D Del, Pellegrini N and Feo V De, 2012. Compositional study and antioxidant potential of *Ipomoea hederacea* Jacq. and *Lepidium sativum* L. seeds. *Molecules* 17(9): 10306–10321. <https://doi.org/10.3390/molecules170910306>