

The Evaluation and Management of Congenital Loss of the Pericardium in A Cat: A Case Report

Chattida Panprom¹, Sirada Tayayouth¹, Nakrob Pattanapon¹, Wannisa Meepoo¹ and Soontaree Petchdee^{2*}

¹Kasetsart University Veterinary Teaching Hospital, Faculty of Veterinary Medicine, Kasetsart University, Kamphaeng Saen, Nakorn Pathom, Thailand

²Department of Large Animal and Wildlife Clinical Science, Faculty of Veterinary Medicine, Kasetsart University, Kamphaeng Saen Nakorn Pathom, Thailand

*Corresponding author: fvetstr@ku.ac.th

Article History: 22-130

Received: 03-Feb-23

Revised: 17-Feb-23

Accepted: 20-Feb-23

ABSTRACT

An 8-month-old female British shorthair cat presented for a routine health screening. The radiography examination showed an unusual cardiac silhouette around the cardiac apex. The ECG segment from S wave to the T wave (ST segment) is elevated and reveals a counterclockwise deviation of the cardiac axis. An echocardiographic examination demonstrated the loss of the pericardium over the right area of the heart. After a final diagnosis of partial absence of the pericardium, diaphragmatic plication was performed to prevent diaphragmatic herniation. This surgical technique can be selected as a treatment choice to prevent and repair the diaphragm. The partial loss of the pericardium is a rare congenital malformation that rarely occurs in veterinary medicine. This is the first report describing the diagnosis and prevention of a partial loss of the pericardium in cats.

Key words: Cat, Defect, Pericardium, Diaphragmatic Plication.

INTRODUCTION

The loss of the pericardium is an uncommon congenital malformation generally characterized by nonspecific symptoms (El Khoury et al. 2021). The pericardium may be lost due to a genetic anomaly, and the absence of the pericardium is usually detected incidentally during health screening (Shah et al. 2015; Aslan et al. 2021). The lack of the pericardium is an occasional finding with no specific clinical signs and uncommonly shows in clinical signs such as pericardial effusion and cardiac tamponade (Chapel et al. 2014). However, the adhesions of the apex to the diaphragm may be noticed in feline patients and no necessary treatment in patients with an absence of the pericardium (Foo et al. 2018). However, patients with the loss of the pericardium may have a chance of herniation due to the thin layer of the diaphragm in these patients, and surgical procedure with diaphragmatic plication was reasonable for this case (Chapel et al. 2014).

Case History: An 8-month-old cat was referred to the cardiology clinic after a health screening. A repeat

electrocardiogram showed abnormal ST segment elevation, low voltage on the bipolar limb leads, and aberrant ventricular complexes in the chest leads (V4 and V6) (Fig. 1), as well as a chest X-ray showing an unusual cardiac silhouette around the apex (Fig. 2). The cat showed no clinical signs and was physically active. Blood samples were collected for routine hematological and biochemical investigations (Table 1). A chest X-ray and echocardiogram were performed for the diagnosis. During the physical examination, echocardiography demonstrated the loss of the pericardium over the left side of the heart. The heart apex was found to adhere to the diaphragm (Fig. 3). The cat underwent surgical correction to prevent diaphragmatic herniation using a nonabsorbable suture (Fig. 4). The cat was intravenously administered with cefixime (5mg/kg IV q12h) and lactated Ringer's solution (5mg/kg/h).

The Thoracic X-Ray

Chest X-ray showed an unusual cardiac silhouette, coexisting with the straightening and elongation of the left cardiac border was observed (Fig. 2).

Cite This Article as: Panprom C, Tayayouth S, Pattanapon N, Meepoo W and Petchdee S, 2023. The evaluation and management of congenital loss of the pericardium in a cat: A case report. International Journal of Veterinary Science x(x): xxxx. <https://doi.org/10.47278/journal.ijvs/2023.017>

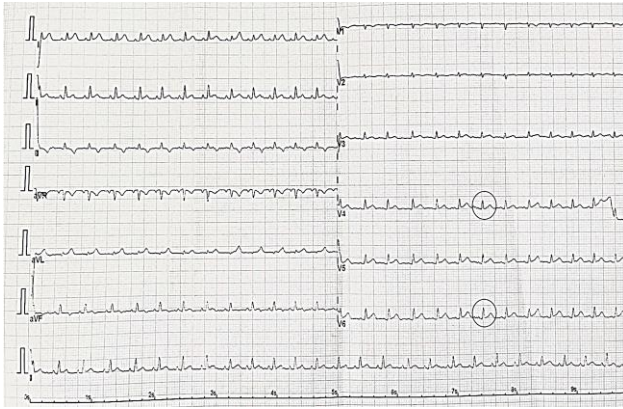


Fig. 1: Twelve leads electrocardiogram showing low voltage in the limb leads and aberrant ventricular complex in precordial leads V4 and V6 (circle). There is also evidence of an ST elevation in all leads (10mm/mV, 25mm/s).

Transthoracic Echocardiography

An echocardiographic examination was performed using a General Electric Vivid 5 s ultrasound machine for cardiovascular investigation, as described in the previous report (Pamprom et al. 2021). The echocardiographic examination was recorded and evaluated before and after

the diaphragmatic repair (Table 2). The heart characteristic and function measurements were performed in long- and short-axis views with no sedation during diastole and systole to gain the echocardiography parameters. The cardiac structure and function were calculated by assessing the images from two-dimensional and M-mode planes.

Diaphragmatic Repair

The cat was premedicated and induction with intravenous fentanyl (50mcg/kg) and alfaxalone (1mg/kg), respectively. Anesthesia was continued with isoflurane at a concentration of 2-5%. A 12 leads electrocardiogram was used to determine the cardiac electrical activities. The ventral midline incision from the xiphoid extended caudally approximately 5 cm was cut for the diaphragmatic repair (Fig. 4). Diaphragm plication was performed with 3-0 monofilament nonabsorbable sutures, and the skin was closed with surgical nylon. After the surgical repair of the diaphragm, the hematological profiles of the cat showed slight anemia with a decreased packed cell volume (PCV). The biochemical blood profiles demonstrated elevated hepatic enzymes such as alkaline phosphatase (ALP), as shown in Table 1.

Table 1: Signalment, hematological, and serum biochemical profiles before and after diaphragmatic repair of British short hair female cat of 8 months age

Parameters	Units	Before Surgery	After 3 days post-surgery	Reference values
White Blood Cell (WBC)	$\times 10^3/\mu\text{L}$	10.44	9.79	5.5-19
Red Blood Cell (RBC)	$\times 10^6/\mu\text{L}$	6.53	4.15	5-10
Hemoglobin (HGB)	gm%	10.5	11.1	10-15
Pack Cell Volume (PCV)	%	34.7	30.8	30-45
Band neutrophil	$\times 10^3/\mu\text{L}$	-	0.61	0-0.3
Segmented neutrophil	$\times 10^3/\mu\text{L}$	4.88	5.0	2.5-12.5
Lymphocyte	$\times 10^3/\mu\text{L}$	5.7	3.7	1.5-7.0
Monocyte	$\times 10^3/\mu\text{L}$	0.21	0.44	0-8.5
Eosinophil	$\times 10^3/\mu\text{L}$	0.05	0.06	0-7.5
Blood Urea Nitrogen (BUN)	mg%	23	22	15-34
Creatinine	mg%	1.7	1.4	<2.0
Total Protein	gm%	6.7	6.2	5.8-7.8
Alanine transaminase (ALT)	U/L	41	39	28-76
Aspartate amino transferase (AST)	U/L	23	29	12-40
Alkaline phosphatase (ALP)	U/L	69	72	0-62

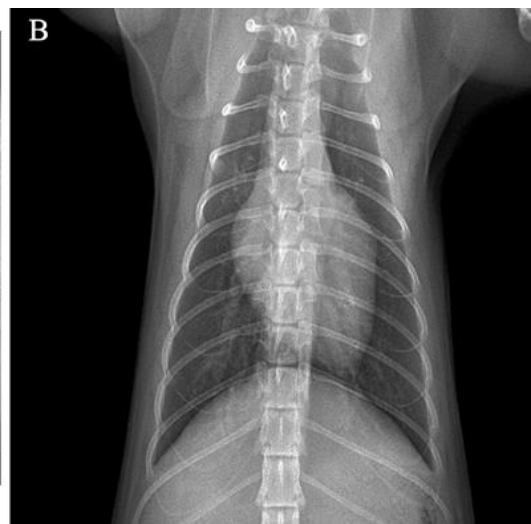
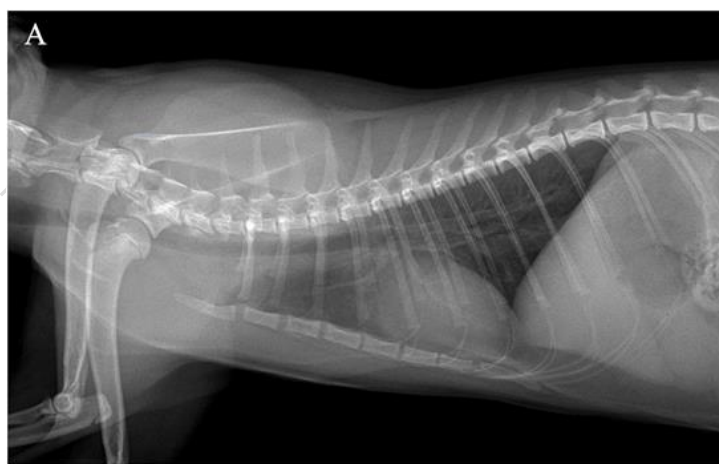


Fig. 2: A) Right lateral and ventrodorsally, and B) chest X-ray showing a posterior shift of the cardiac silhouette and loss of the right heart border.

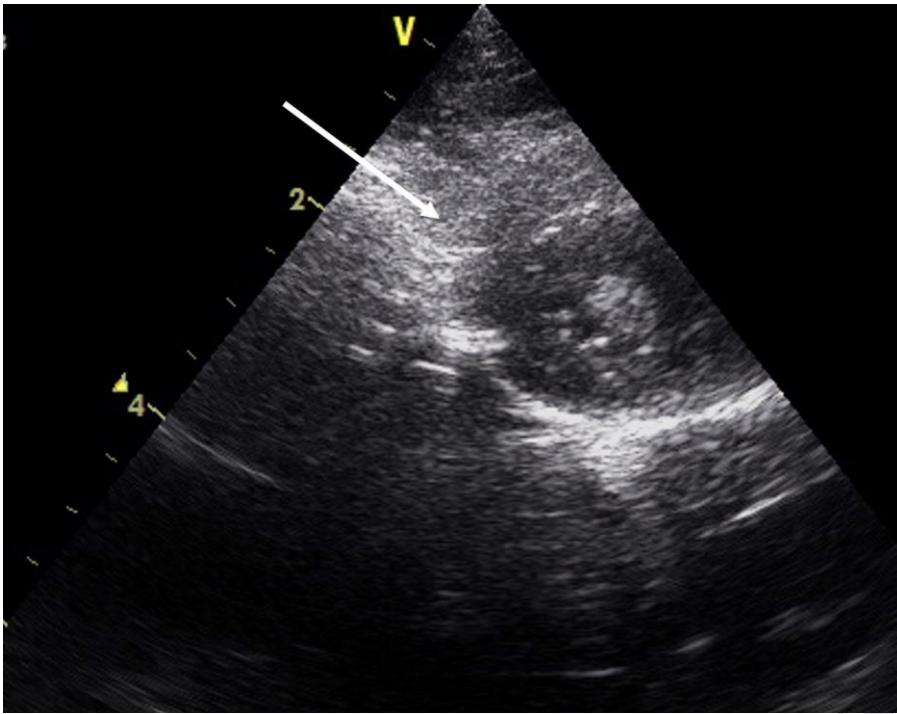


Fig. 3: Short axis view of the heart showing the absence of the pericardium over the right side of the heart (arrow).

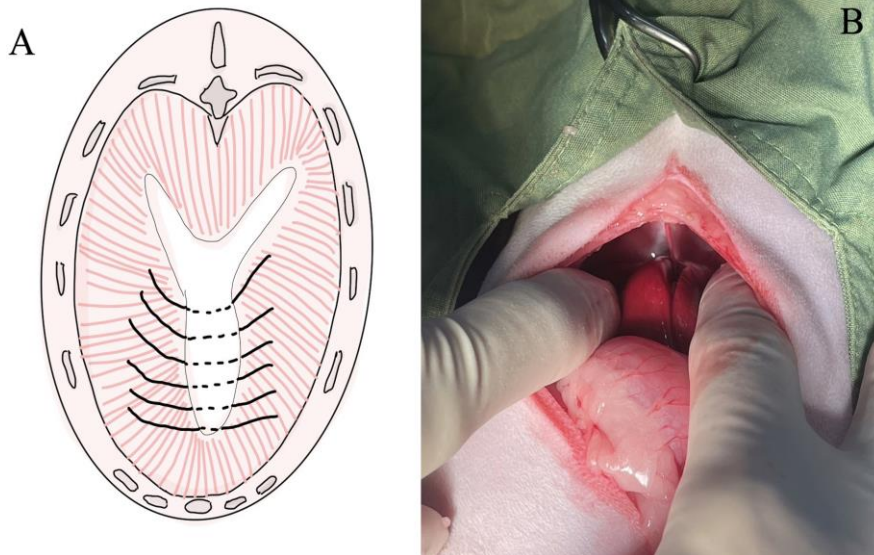


Fig. 4: Artistically image, A) demonstrates the surgical technique of diaphragmatic plication, and B) the surgical site for diaphragmatic plication.

Table 2: Echocardiography parameters before and after surgical repair of the diaphragm in cat

Echocardiography Parameters	Before Surgery	3 days after surgery
IVSs (cm)	0.5	0.5
IVSd (cm)	0.6	0.6
LVIDs (cm)	1.0	1.1
LVIDd (cm)	1.6	1.6
LA:Ao	1.63	1.62
FS (%)	37.5	31.5
FAC (%)	62	58
TAPSE (cm)	0.9	0.8
Heart rate (bpm)	166	150
VHS	8.6	8.6

IVSs = Interventricular septal at end-systole; IVSd = Interventricular septal at end-diastole; LVIDs = Left ventricular internal diameter at end-systole; LVIDd = Left ventricular internal diameter at end-diastole; LA = Left atrium; AO = Aorta; FS = Fractional shortening; FAC = Fractional area change; TAPSE = Tricuspid annular plane systolic excursion; VHS = Vertebral heart score.

DISCUSSION

The layers of the pericardium consist of an external fibrous layer and an internal serosal layer. The pericardium stabilizes and maintains the heart's position in the thoracic cavity (Chang et al. 2010; Foo et al. 2018). Congenital absence of the pericardium is a rare condition and left-sided defects are more common (Verde et al. 2013). Chest X-rays commonly show a posterior shift of the cardiac silhouette and loss of the right heart border (Garnier et al. 2010). On ECG, there is often low voltage of the R-wave due to the axial rotation of the heart (Foo et al. 2018). A congenital absence of the pericardium diagnosis can be made by radiographic and transthoracic echocardiography (Xu et al. 2017; Hoek et al. 2018; Loughran et al. 2019). However, magnetic resonance imaging (MRI) and computed tomography (CT) can confirm the diagnosis of an unclear case (Alyami et al. 2022). In this case, surgical treatment was chosen in this

study to plicate and repair the defect and prevent further herniation. In general, a surgical correction should be performed on a cat with a complete absence of the pericardium to stabilize the heart and avoid the herniation of heart structures (Fossum 2007). This treatment method has some limitations, but the diaphragmatic plication technique used in this case can prevent further herniation. However, the severe adhesion of the myocardium can cause compliance with heart failure and myocardial ischemia and might increase the risk of severe cardiac axis deviation. Further management using pimobendan is necessary to help the heart contract, and the cat should be scheduled for a routine follow-up examination.

Congenital partial absence of the pericardium is a rare clinical condition that may be detected incidentally, and some patients present as asymptomatic. A systematic approach using physical examination, electrocardiography, chest X-ray, and echocardiography should be used to determine congenital partial loss of the pericardium diagnosis. Advanced cardiovascular imaging, such as cardiac CT scans, may assist with surgical planning and risk stratification in severe cases.

Conclusion

This surgical method of diaphragmatic plication was safe, provided a desirable prognosis, and had the potential to prevent further herniation. This study recommended that diaphragmatic plication and repair could be applied as a potential therapeutic for the congenital partial loss of the pericardium in dogs and cats.

REFERENCES

- Alyami B, Alharbi A, Alhajji M, Gendi S and Hamirani YS, 2022. A case report of congenital absence of the pericardium that was diagnosed by cardiac computed tomography angiogram (CCTA). *Radiology Case Reports* 17(9): 3380-3384. <https://doi.org/10.1016/j.radcr.2022.06.066>
- Aslan E, Maslak İC and Karabulut N, 2021. Congenital absence of the pericardium. *Türk Kardiyoloji Dernegi Arsivi* 49(8): 696-697. <https://doi.org/10.5543/tkda.2021.21132>
- Chang SA, Kim HK, Kim YJ, Cho GY, Oh S and Sohn DW, 2010. Role of pericardium in the maintenance of left ventricular twist. *Heart* 96(10): 785-790. <https://doi.org/10.1136/hrt.2009.182345>
- Chapel E, Russel D and Schober K, 2014. Partial pericardial defect with left auricular herniation in a dog with syncope. *Journal of Veterinary Cardiology* 16(2): 133-139. <https://doi.org/10.1016/j.jvc.2014.02.001>
- El Khoury A, Zayour M, Hanna C, Janji M and Nasr SR, 2021. Congenital partial absence of pericardium in an elderly patient. *Cureus* 13(10): e18437. <https://doi.org/10.7759/cureus.18437>
- Foo JS, Koh CH, Sahlén A, Tang HC and Lim CP, 2018. Congenital partial absence of pericardium: a mimic of arrhythmogenic right ventricular cardiomyopathy. *Case Reports in Medicine* 2018: 4297280. <https://doi.org/10.1155/2018/4297280>
- Fossum TW, 2007. Surgery of the lower respiratory system: pleural cavity and diaphragm. In: Fossum TW (ed), *Small Animal Surgery*, 3rd Ed. Mosby Inc, St. Louis, USA, pp: 896-929.
- Garnier F, Eicher JC, Philip JL, Lalande A, Bieber H, Voute MF, Brenot R, Brunotte F and Wolf JE, 2010. Congenital complete absence of the left pericardium: a rare cause of chest pain or pseudo-right heart overload. *Clinical Cardiology* 33(2): E52-E57. <https://doi.org/10.1002/clc.20607>
- Hoek I, Payne JR, Feugier A and Connolly DJ, 2018. Inter-observer variability for cardiac ultrasound measurements in cats repeated at different time points in early adult life. *Veterinary and Animal Science* 5: 44-46. <https://doi.org/10.1016/j.vas.2018.03.002>
- Loughran KA, Rush JE, Rozanski EA, Oyama MA, Larouche-Label É and Kraus MS, 2019. The use of focused cardiac ultrasound to screen for occult heart disease in asymptomatic cats. *Journal of Veterinary Internal Medicine* 33(5): 1892-1901. <https://doi.org/10.1111/jvim.15549>
- Panprom C, Jiwaganont P, Bootcha R and Petchdee, S 2021. The surgical repair of a congenital peritoneopericardial diaphragmatic hernia in Maine Coon cat. *Veterinary Integrative Sciences* 19(3): 439-447. <http://doi.org/10.12982/VIS.2021.036>
- Shah AB and Kronzon I, 2015. Congenital defects of the pericardium: a review. *European Heart Journal Cardiovascular Imaging* 16(8): 821-827. <https://doi.org/10.1093/ehjci/jev119>
- Verde F, Johnson PT, Jha S, Fishman EK and Zimmerman SL, 2013. Congenital absence of the pericardium and its mimics. *Journal of Cardiovascular Computed Tomography* 7(1): 11-17. <https://doi.org/10.1016/j.jcct.2013.01.003>
- Xu B, Betancor J, Asher C, Rosario A and Klein A, 2017. Congenital absence of the pericardium: A systematic approach to diagnosis and management. *Cardiology* 136(4): 270-278. <https://doi.org/10.1159/000452441>