



Drug Resistance and Coccidiosis Effects on Immunity, Performance, Blood Micronutrients and Intestinal Integrity in Broiler Chickens

FMF Hayajneh^{1*}, A Abdelqader¹, H Zakaria¹, M Abuajamieh¹ and SA Araj²

¹Department of Animal Production, ²Department of Plant Protection, School of Agriculture, University of Jordan, Amman 11942, Jordan

*Corresponding author: firashope@gmail.com

Article History: 23-196

Received: 07-May-23

Revised: 15-May-23

Accepted: 22-May-23

ABSTRACT

This study investigates anticoccidial drug resistance, coccidiosis effects on growth performance, intestinal lesions, and immunity of broiler chickens against Newcastle and infectious bursal disease. Magnesium, iron, and phosphorus blood concentration changes associated with coccidiosis were also determined. Five equal treatments were randomly assigned to 375 (Ross 308) one-day-old broiler chicks. These chicks were raised for 29 days. Each treatment was divided into three replicates with 25 birds/replicate. On day 12, groups were challenged with coccidiosis. All groups showed clinical signs of coccidiosis. A partial resistance against diclazuril and limited efficacy against a combination of Nicarbazin and Narasin was found. A significant ($P < 0.05$) difference in production performance was found between groups. Iron, magnesium, and phosphorus concentrations in the blood were higher in the 3rd week. The highest infectious bursal disease (IBD) antibody concentrations were noticed in the negative control group, and the highest Newcastle (ND) antibody titer was noticed in T_N and T_{+ve} groups. It was concluded that resistance has developed against anticoccidial drugs. Coccidiosis affects immunity and renders mortality.

Key words: Coccidia, Immunity, Drug resistance, Minerals, Performance parameters

INTRODUCTION

Coccidiosis is an important disease that affects broiler chickens. It is caused by parasites belonging to the Genus *Eimeria*, which cause tissue damage. It disturbs the metabolism of poultry, causing dehydration, blood loss, poor skin pigmentation, and increased susceptibility to other diseases. The clinical signs of coccidiosis include diarrhea, poor growth, impaired feed conversion ratio (FCR) and mortality (Lee and Lillehoj 2022; Taylor et al. 2022). Different species of avian coccidia are involved in this disease, such as *Eimeria acervulina*, *Eimeria necatrix*, *Eimeria brunetti*, *Eimeria tenella* and *Eimeria maxima* (Alam et al. 2021; Mesa et al. 2021; Mares et al. 2023). Each species has a particular site in the digestive tract (Hayajneh et al. 2020).

Prevention of coccidiosis can be done using coccidiostats/coccidiocidals. These drugs have been used for a long time, and together with misuse of these drugs; these protozoan parasites have developed resistance to these drugs (Dardi et al. 2018; Flores et al. 2022; Martins et al. 2022; Martins et al. 2023).

The most common method for coccidiosis treatment is chemotherapy. Misuse and long-term use of these drugs led to the development of anticoccidial drug resistance (Abbas et al. 2009, 2011; Chapman and Blake 2022; Chapman and Rathinam 2022). Diclazuril is used against coccidiosis; this drug possesses significant activity against different stages of *Eimeria* species (Abbas et al. 2009). Diclazuril disrupts the oocyst wall of *Eimeria* species (El-Ashram et al. 2019; Salem et al. 2022). Nicarbazin is another drug commonly used as a coccidiostat in poultry feed alone or combination with Narasin (Lima et al. 2017; Künzel et al. 2019; Martins et al. 2022). Different methods are used to detect drug resistance (Morris et al. 2007; Tan et al. 2017). In this study, drug sensitivity was determined by the global index (GI) (Thabet et al. 2015).

There is scarce information about the development of resistance in *Eimeria* species against commonly used anticoccidial compounds in Jordan; the present study aimed to investigate resistance to the commonly used anticoccidials. This study also investigated the effect of coccidiosis on immunity against ND and IBD diseases, the changes in blood mineral concentrations, and intestinal histopathological changes associated with coccidiosis.

Cite This Article as: Hayajneh FMF, Abdelqader A, Zakaria H, Abuajamieh M and Araj SA, 2023. Drug resistance and coccidiosis effects immunity, performance, blood micronutrients and intestinal integrity in broiler chickens. International Journal of Veterinary Science x(x): xxx. <https://doi.org/10.47278/journal.ijvs/2023.054>

MATERIALS AND METHODS

Animal Ethics

The Scientific Research Council of the University of Jordan approved the experiment's protocols vide number (135/2022). Animals were reared and treated as per the EU Directions 2010/63/EU.

Study Place

This research was done at the poultry production unit at Jordan University Station for Dry Land Research at Al-Muwaqqar, located 45km southeast of Amman, Jordan. The closed house consisted of 10 rooms which were provided with stoves, drinkers, feed troughs, and a lighting system.

Experimental Design and Birds Management

This experiment was conducted using a Randomized Complete Block Design (RCBD). A-day old 375 chicks (Ross 308) were purchased from the local market. Chicks were allowed to acclimatize for 10 days; on day 12, the chicks were divided randomly into 5 equal groups/treatments; each treatment consisted of three replicates (25 birds each). All chicks had close initial body weight (35-40g). Feed and water were provided *ad libitum*. Chicks were reared on the floor covered with wood shavings. Nutrient requirements and management practices were applied according to the breed guidelines. Chicks were reared according to standard management practices. All chicks were fed the broiler's starter ration until week 2 and, after that, fed a finisher ration (Table 1). The pen temperature was kept at 29-32°C during the first week of age; after that, the temperature was reduced by 0.5°C weekly. The light was provided for 24h throughout the experimental period. The birds were separated into the assigned groups on day 12, and the medications were added to feed on day 12 for 7 days after inoculation with oocysts. The birds were vaccinated for infectious bursal disease and Newcastle disease.

Drugs and Administration

On day 12, the drugs were given to birds daily until day 7 post-inoculation with oocysts. In all groups, a basal diet was offered *ad libitum*. Diclazuril (Avico, Amman, Jordan) was mixed with drinking water @ 1.2mg/kg in the T_D group, a combination of Nicarbazin and Narasin (Elanco, Amman, Jordan) was mixed in feed @ 100g/kg in the T_N group and the positive control group (T_{+ve}) a commercial toxin binder, i.e., was mixed with feed. Bentonite (Elanco, Amman, Jordan) 1.5mg/kg was administered. In the negative control groups, T_{-ve1} and T_{-ve2}, no treatments were added, and the birds in T_{-ve1} were infected with infected coccidial cysts, while birds in T_{-ve2} were not infected; all birds in other groups were infected and fed various drugs (Table 2). Drug doses were given according to manufacturer instructions.

Coccidiosis Induction

Birds infected with coccidiosis were naturally collected from local farms, and infectious coccidial oocysts were isolated, as described by Hayajneh et al. (2020), according to the site of infection and oocyst morphology including size, shape and color after sporulation,

five species were identified: *E. acervulina* (10%), *E. brunette* (13%), *E. maxima* (12%), *E. necatrix* (12%) and *E. tenella* (57%). On 14 days, coccidiosis was introduced in broiler chicks via the oral route and each chicken received an infectious coccidian dose 3x10⁵/bird (Abbas et al. 2011).

Table 1: Composition of broiler basal feed (g/kg)

Ingredients	Starter (0-21 d)	Finisher (22-28 d)
Maize	540.0	710.0
Soybean meal (480g/kg CP)	360	250.0
Dicalcium phosphate	20	20.0
Soybean oil	13	13.0
Fish meal	60	0
DL-Methionine	1.5	0.5
Vitamin-mineral premix ^{a,b}	3.5	3.5
Sodium chloride	2.0	3.0
Chemical composition (g/kg diet as fed basis)		
ME _N (MJ/kg)	12.6	13.0
Crude protein	235.0	182.0
Calcium	12.3	8.0
Total Phosphorus	6.5	5.1
Lysine	17.0	10.0
Methionine	9.0	8.0

^aVitamin premix provided per kilogram of diet: Vitamin A=0.5760; Vitamin K=?IU; Vitamin B5=19.4532mg; Tocopherol=4.6799mg; Vitamin B1=3.5016mg; Vitamin B2=1.6994mg; Vitamin B6=6.4911mg; Vitamin B12=16mg; Biotin=0.1382mg; Folic Acid=1.2692mg; Pantothenic=7.8104mg; Vitamin K3=0.9071mg; ^bTrace mineral premix per kg diet were: Iron= 62.0061mg; Zinc=43.065mg; Copper=6.855mg; Iodine=0.0589mg; Selenium=1.3466mg. Soybean concentrate and mono-calcium phosphate were also provided.

Performance Parameters

Feed intake, body weight, average feed intake, and feed conversion ratio (FCR) were calculated on days 14, 21 and 28. Also, oocysts per gram of feces, lesion score, and oocyst scoring were recorded on days 14, 21 and 28. Health aspects and mortality were monitored daily. Efficacy status was calculated as a percentage of the GI for the NNC.

Lesion Scoring and Oocyte Index

On days 7 and 14 post-inoculation (experimental days 21 and 28), three birds from each replicate were randomly selected and killed humanely for coccidial lesions scoring. A score of 0 to +4 was recorded for each chicken (Abbas et al. 2009; Raman et al. 2011). An Oocyst index of 0 to 5 was determined after examining scrapings from birds sacrificed for lesion scoring on days 7 and 14 post-inoculation. The oocyte index was determined according to the method described by Abbas et al. (2009) and Arabkhazaeli et al. (2013).

Minerals Measurements

Blood from randomly selected birds from each group was collected without anticoagulant. The serum was extracted and stored at -20°C till analysis. Ion, phosphorus, and magnesium were measured by spectrophotometry using kits (Biosystems, Barcelona, Spain).

Antibodies Measurements

To measure the titer of Newcastle and infectious bursal disease antibodies in the serum, a commercial ELISA kit from BioChek Immunoassays (BioCheck, Reeuwijk,

Table 2: Layout of experiment study

Group/Treatment	Drug Used	Dose	Coccidiosis Introduced
T _N (medicated)	Nicrabazin and Narasin	100g/kg	Yes
T _D (medicated)	Diclazuril	1.2mg/kg	Yes
B _M (medicated: T _{+ve})	Bentonite	1.5mg/kg	Yes
INC (T _{-ve2})	Infected nonmedicated control	-	Yes
NNC (T _{-ve1})	Noninfected, nonmedicated control	-	No

T_N=Nicrabazin and narasin -medicated group; T_D=Diclazuril-medicated group, T_B=Bentonite medicated group (T_{+ve}), INC=Infected nonmedicated controls (T_{-ve2}); and NNC=Noninfected, nonmedicated control (T_{-ve1}).

Netherlands) was used according to the manufacturer's guidelines. The cut-off used was <0.35. The tests were performed in Feedco Labs, Jordan.

Histopathological Examination

Tissue samples from morbid intestines were collected for histopathological studies. Morbid tissues were preserved in 10% buffered formalin and processed for histopathological studies using the routine method of dehydration and embedding in paraffin. Sections 4–5µm thick were cut and stained with hematoxylin and eosin (Hayajneh et al. 2020). Prepared slides were examined under a light microscope.

Evaluation of Sensitivity or Resistance

Seventeen chicks were randomly selected on day 12 from each group, weighed, and then reweighed on day 21; the body weight gain difference was calculated between these days. Five chicks from each group were sacrificed on day 21, and the intestinal lesion score was recorded according to the method described by Abbas et al. (2009). After microscopic examination of intestinal scrapings taken from sacrificed birds, the oocyte index was determined (0-5) according to described by Arabkhazaeli et al. (2013). The sensitivity of drugs was determined using the global index (GI), and the GI was calculated using the formula used described by Abbas et al. (2009).

Statistical Analysis

SPSS software was used to analyze collected data. One-way analysis of variance was used, and the means of different treatments were compared with Tukey tests and a repeated-measure test. Values were considered statistically different at $P \leq 0.05$, and the mean values were compared using Tukey's test. The means of each isolate were compared separately.

RESULTS

Physical Parameters

All groups showed signs of coccidiosis which included blood in feces and scattered white plaque-like lesions containing developing oocysts. T_D and T_{+ve} groups were classified as lesion score 1; group T_N showed lesions, which coalesced. The intestinal walls did not show thickening. Digestive tract contents were normal and scored as lesion score 2. An increase in the number of oocysts in feces was noticed. Excessive tissue damage and hemorrhage were seen during histopathological examinations of the affected intestines. Schizonts and merozoites were seen, and coccidian oocysts were also seen in the lumen.

A partial resistance against diclazuril and limited efficacy against a combination of Nicrabazin and Narasin were found (Table 3). A significant difference was noticed between groups in initial body weight, final body weight, average body gain and average feed intake (Table 4). The highest ($P < 0.05$) FCR was calculated in the negative control group (T_{-ve2}), which did not receive any medication against coccidiosis, and the significantly ($P < 0.05$) low FCR was noticed in the T_D and T_N groups, which received medication (Diclazuril) and Nicrabazin and Narasin, respectively (Table 4).

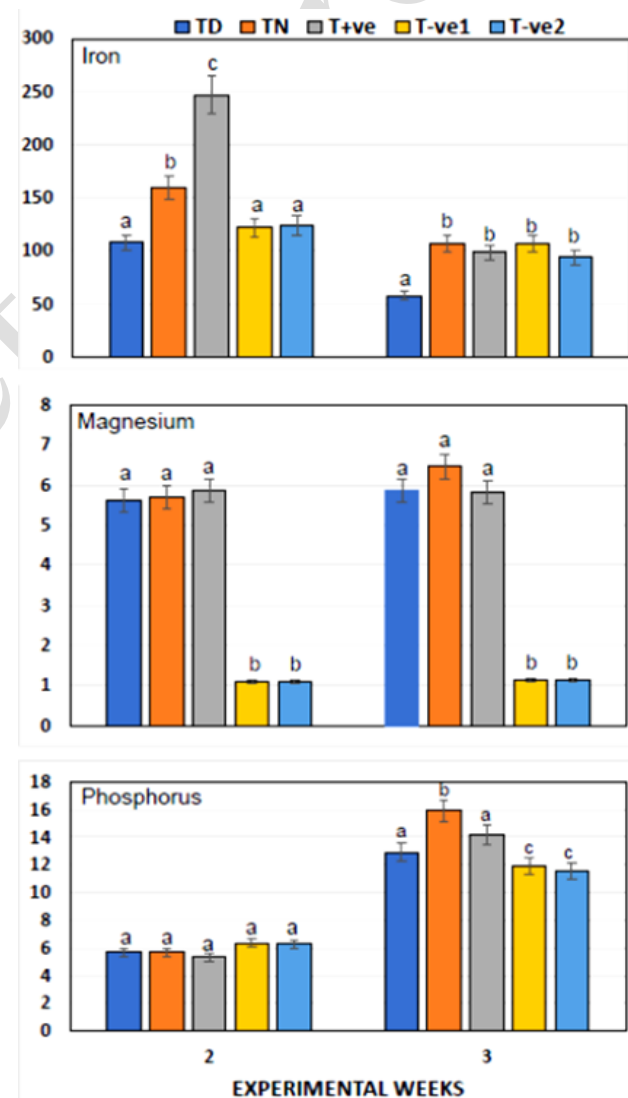


Fig. 1: Serum iron (mg/dL), magnesium (mg/dL), and phosphorus (mg/dL) concentration in of broiler chicks feed various doses of anticoccidial drugs at various experimental days. Bars bearing different alphabets within experimental week under specific mineral differ significantly ($P < 0.05$).

Table 3: Comparative values of FCR, lesion score, oocyst index, mortality percentage, global index, and efficacy status

Group	FCR (g/g)	Lesion score	Oocyst index	Mortality (%)	GI%	The global index of NNC (%)	Efficacy status
T _N	1.37	2	1	6.6	71	73.2	3
T _D	1.5	1	0	5.3	64.9	66.3	4
T _B	1.4	1	5	1.3	70.65	71.2	3
NNC	1.67	1	4	1.3	----	----	----
INC	1.7	1	4	2.6	----	----	----

T_N=Nicarbazin and narasin -medicated group; T_D=Diclazuril-medicated group, T_B=Bentonite medicated group (T_{+ve}), NNC=Noninfected, nonmedicated control (T_{-ve1}). INC=Infected nonmedicated controls (T_{-ve2}); Global index (GI) = %WGNNC – [(FM – FNNC) × 10] – (OIM – OIINC) – [(LSM – LSINC) × 2] – (%mortality/2), where WG is weight gain, F is the FCR, OI is the oocyst index, LS is the lesion score, M is the medicated group, NNC is the noninfected, nonmedicated control group, and INC is the infected nonmedicated control group. Efficacy status was calculated as a percentage of the GI for the NNC. The following 5 categories were used for testing resistance to anticoccidials: 1) very good efficacy, ≥90% GINNC; 2) good efficacy, 80 to 89% GINNC; 3) limited efficacy, 70 to 79% GINNC; 4) partially resistant, 50 to 69% GINNC; and 5) resistant.

Table 4: Weight gain, feed intake and FCR of broiler chicks feed various doses of anticoccidial drugs

Parameters	Treatment Groups					SEM
	T _D	T _N	T _B	T-VE1	T-VE2	
Initial body weight (D 0), g	37.8a	37.0a	37.4a	36.7a	37.7a	0.84
Final body weight (D 28), g	1012.5a	1090.8a	1077.1a	1030.8a	1032.8a	53.8
Average body gain, g	974.7a	1053.8a	1039.7a	994.1a	995.1a	53.6
Average feed intake, g/period	1378.9c	1454.1bc	1675.9a	1612.7ab	1613.7ab	58.2
FCR (Feed Conversion Ratio)	1.41b	1.38b	1.62a	1.63a	1.62a	0.05

Values bearing different letters in the same row are significantly different at P<0.05; Tukey test after a significant one-way-ANOVA (P<0.05). SEM=Pooled standard error of the mean.

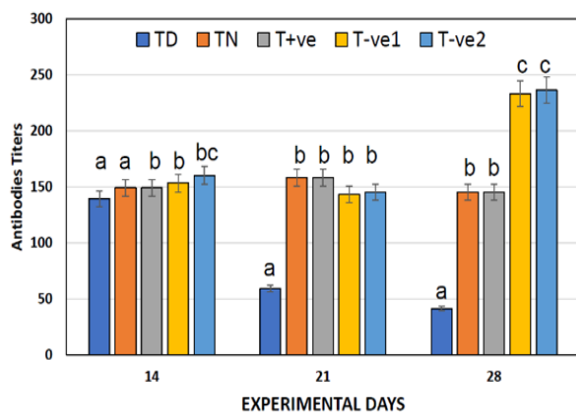


Fig. 2: Antibodies titers of infectious bursal disease virus of broiler chicks feed various doses of anticoccidial drugs at various experimental days. Bars bearing different alphabets within experimental day differ significantly (P<0.05).

Mineral Analysis

As shown in Fig. 1, after week 2 the highest iron concentration is shown in T_{+ve} group, and the lowest is in T_D group, but in week 3 the highest is seen in T_N group and the lowest in T_{-ve2} group. For magnesium the highest concentration is seen in T_{+ve} group and the lowest in T_{-ve2} group in week 2, in week 3 T_N shows the highest concentration and T_{-ve2} remains the lowest, T_N group shows a slight increase. For phosphorus there is a clear increase in the concentration in all tested groups, and the highest concentration is seen in T_N group in week 3.

Antibodies Titration

As shown in Fig. 2, the highest concentration of IBD antibodies appear in the negative control groups and the lowest concentration appears in T_D and T_N groups, similar concentrations are noticed in T_{+ve} and T_N groups. In Fig. 3 the highest concentration of ND antibodies appears in T_D group on day 14, this concentration in this group is the

lowest on day 28, the lowest ND antibody concentration is in T_N and T_{+ve} group on day 14, which increases and is the highest on day 28, T_N shows the highest ND antibody concentrations on day 21 and 28.

DISCUSSION

Scanty information about drug resistance of *Eimeria* spp. against diclazuril and Nicarbazin anticoccidial drugs is available in Jordan. Results of the current study are in accordance with the results reported by Peek et al. (2003), and Arabkhazaeli et al. (2013), who found no sensitivity to the used anticoccidial drugs in their experiments. Peek et al. (2003) also found reduced sensitivity to Nicarbazin and Narasin. Partial to complete resistance to amprolium+ethopabate has also been reported previously (Abbas et al. 2011). Resistance against Nicarbazin and diclazuril is also documented (Peek et al. 2003; Bafundo et al. 2008; Abbas et al. 2011; Attree et al. 2021; Flores et al. 2022; Glorieux et al. 2022). The results of Lan et al. (2017) also showed resistance against 8 anticoccidial drugs.

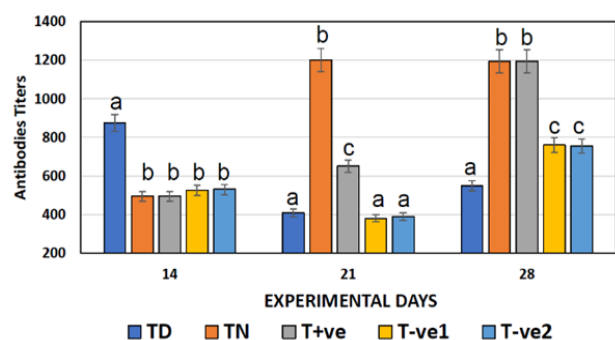


Fig. 3: Antibodies titers of Newcastle disease virus of broiler chicks feed various doses of anticoccidial drugs at various experimental days. Bars bearing different alphabets within experimental day differ significantly (P<0.05).

Coccidiosis is chiefly controlled using coccidiostats administration in feed (Shirley et al. 2005). Drug resistance in *Eimeria* is common because of extensive use of anticoccidial drugs for the control of avian coccidiosis (Lillehoj and Lillehoj 2000; Bozkurt et al. 2016; Khater et al. 2020). Because of drug resistance, pharmaceutical coccidiostats are becoming less effective in controlling coccidiosis in avian species (Abbas et al. 2011; Lillehoj and Lee 2012). There could be another possibility of the development of resistance that underdose of anticoccidial used in feeds could lead to resistance (Dauguschies et al. 1998; Usman et al. 2011). The continuous use and misuse of anticoccidial drugs have led to the emergence of drug-resistant strains (Ruff and Danforth 1996).

Kawazoe and Difabio (1994) reported that diclazuril was effective against strains that have never been exposed to the drugs, while resistance to the drug in field isolates of *Eimeria* (*E. acervulina*, *E. maxima*, and *E. tenella*) following use of the drug was possible. Isolates of *E. tenella* were resistant to Nicarbazin while fully sensitive to meticlorpindol plus methylbenzoate in the battery and field trials (Usman et al. 2011). Abbas et al. (2008) reported that none of the *E. tenella* field isolates showed complete sensitivity or complete resistance to the anticoccidials used (salinomycin, maduramicin, and clodol). Multiple resistance among diclazuril, Nicarbazin, and toltrazuril has been reported previously (Stephen et al. 1997; Bo et al. 2020; Huang et al. 2022).

Feed conversion ratio (FCR) is the mass of feed eaten divided by the output over a given period and is a performance measure (Willems et al. 2013). In the present study, a significant ($P < 0.05$) difference was found between groups in this study regarding production parameters. Da Costa et al. (2017) and Vereecken et al. (2020) reported coccidiosis lesions suppressed by Nicarbazin, thus improving coccidial lesion scores and ultimately improving FCR. Very poor sensitivity against Nicarbazin and Narasin was also found by Glorieux et al. (2022). The main effect of the coccidia challenge was reduced starch digestibility, which was reported by Amerah and Ravindran (2015). Assis et al. (2012) found that diclazuril significantly improved birds infected with coccidiosis. A combination of Nicarbazin and Narasin increased body weight but reduced FCR (Farran et al. 2020). Diclazuril showed good results against *E. tenella* infection in chickens (Elkomy et al. 2015; Boyko et al. 2021).

All groups in this study showed signs of coccidiosis. When the combination of Nicarbazin and Narasin was first introduced and used, it was reported that this product was the second most effective against field *E. tenella* behind diclazuril, but results reported by Glorieux et al. (2022) demonstrated poor sensitivity to Nicarbazin and Narasin (Glorieux et al. 2022). Results reported by Farran et al. (2020) showed that Nicarbazin and Narasin treatment demonstrated efficacy at reducing coccidian lesions. The results of Assis et al. (2012) indicated a reduction in the count of oocysts and lesion scores in the treated group. Cha et al. (2020) indicated that the addition of diclazuril in the drinking water was effective against coccidiosis in broiler chickens. They also reported reduced oocyst numbers, improved lesion scores, and fecal scores. Variable responses to diclazuril treatment were noticed by Kawazoe

and Di Fabio (1994) depending upon the time of exposure and the type of drug program used.

In the present study, phosphorus, magnesium, and iron concentrations were significantly higher in the third week of age. Magnesium concentrations in the blood increase post-coccidia infection (Cha et al. 2020). Bloody enteritis caused by coccidiosis in chickens disrupts the absorption of magnesium (Hayajneh et al. 2020). The mean value of serum iron and inorganic phosphorus levels in the coccidia-infested group decreased significantly ($P < 0.05$) in comparison with the mean value recorded in the control group, as has also been reported by Turk (1981). Bloody enteritis caused by coccidiosis in chickens reduces magnesium and iron absorption (Toledo et al. 2011). *Eimeria* infection impairs phosphorus status at day 6 post-infection (Oikeh et al. 2019). Coccidiosis affects lipid digestibility and subsequently impairs the absorption of other fat-soluble nutrients, including vitamin D, which can consequently depress the absorption of calcium and phosphorus (Gautier et al. 2020).

Calcium and phosphorus absorption was reduced in infected poultry in the present study. It has been reported that blood phosphorus concentration significantly reduces after coccidial infection in broiler chickens (Freitas 2014). The mechanism for this reduction could be associated with a reduction in the absorptive capacity of the intestine during the *Eimeria* challenge. *Eimeria acervulina* is known to affect intestinal nutrient absorption and metabolism and depresses the absorption of iron (Cha et al. 2020).

As shown in Fig. 2, the highest concentration of IBD antibodies appear in the negative control groups and the lowest concentration appears in T_D and T_N groups, similar concentrations are noticed in T_{+ve} and T_N groups. In Fig. 3 the highest concentration of ND antibodies appears in T_D group on day 14, this concentration in this group is the lowest on day 28, the lowest ND antibody concentration is in T_N and T_{+ve} group on day 14, which increases and is the highest on day 28, T_N shows the highest ND antibody concentrations on day 21 and 28. According to Obasi et al. (2006), the rapid onset of coccidiosis clinical disease and the high mortality was induced by the Newcastle disease vaccine administration. Also, lower antibody titers against Newcastle and infectious bursal disease in infected poultry were reported (Akhtar et al. 2015). A failure to develop protection against commonly used vaccines like ND and IBD vaccines might be a result of coccidiosis infection, which was also reported by Kurkure et al. (2006). Post-parasitic infection, infected animals usually develop transient or permanent immunosuppression (Akhtar et al. 2015).

Anticoccidial drug resistance poses a potential threat to the poultry industry. The best practical preventive method could be anticoccidial drug rotation and shuttle programs. It is necessary to develop strategies to overcome the problem of resistance in *Eimeria* strains and to prolong the effect of available anticoccidial drugs (Abbas et al. 2011; Lan et al. 2017; Flores et al. 2022).

Conclusion

Drug resistance in different degrees (partial to full) against commonly used anticoccidial drugs is present in Jordan. More research work must be done to determine the degree of resistance of other drugs used. This problem must

be overcome by the rotation of anticoccidial drugs and shuttle programs, which are successful in other countries.

Conflict of interest

The authors have no conflict of interest.

Funding

The research was funded by the Jordan University

Authors' Contributions

FMH: Contributed to the conception and designed the study. AM and HZ: Contributed reagents, materials, and analytic tools. FMH Performed the animal experiments. FMH and AM: Did the statistical analysis and interpretation. FMH: Wrote and revised the paper. All authors have read and approved the final manuscript.

Acknowledgement

The authors are very thankful to The Jordan University for financial support and to all the associated personnel in any reference that contributed in/for the purpose of this research.

REFERENCES

- Abbas RZ, Iqbal Z, Sindhu Z-D, Khan MN and Arshad M, 2008. Identification of cross-resistance and multiple resistance in *Eimeria tenella* field isolates to commonly used anticoccidials in Pakistan. *Journal of Applied Poultry Research* 17: 361-368.
- Abbas RZ, Iqbal Z, Khan MN, Hashim N and Hussain A, 2009. Prophylactic efficacy of diclazuril in broilers experimentally infected with three field isolates of *Eimeria tenella*. *International Journal of Agriculture & Biology* 11: 606–610.
- Abbas RZ, Iqbal Z, Blake D, Khan MN and Saleemi MK, 2011. Anticoccidial drug resistance in fowl coccidia: the state of play revisited. *World's Poultry Science Journal* 67(2): 337–350. <https://doi.org/10.1017/S004393391100033X>
- Akhtar M, Awais MM, Anwar MI, Ehtisham-ul-Haque S, Nasir A, Saleemi MK and Ashraf K, 2015. The effect of infection with mixed *Eimeria* species on hematology and immune responses following Newcastle disease and infectious bursal disease booster vaccination in broilers. *Veterinary Quarterly* 35 (1): 21–6. <https://doi.org/10.1080/01652176.2014.991048>
- Alam MZ, Dey AR, Parvin S, Akter S and Rony SA, 2021. ITS1-PCR based identification of chicken *Eimeria* species in poultry litter from Mymensingh district, Bangladesh. *Journal of Advanced Veterinary and Animal Research* 8(3): 489–493. <https://doi.org/10.5455/javar.2021.h538>
- Amerah AM and Ravindran V, 2015. Effect of coccidia challenge and natural betaine supplementation on performance, nutrient utilization, and intestinal lesion scores of broiler chickens fed suboptimal level of dietary methionine. *Poultry Science* 94(4): 673–680. <https://doi.org/10.3382/ps/pev022>
- Arabkhazaeli F, Modrisanei M, Nabian S, Mansoori B and Madani A, 2013. Evaluating the resistance of *Eimeria* spp. Field isolates to anticoccidial drugs using three different indices. *Iranian Journal of Parasitology* 8(2): 234–241.
- Assis RCL, Cury MC, Luns FD and Assis RL, 2012. Anticoccidial efficacy of drinking water soluble diclazuril in the control of *Eimeria acervulina* oocysts on experimentally infected broiler chickens. *Arquivo Brasileiro de Medicina Veterinaria e Zootecnia* 64(5): 1188–1193. <https://doi.org/10.1590/S0102-09352012000500016>
- Attree E, Sanchez-Arsuaga G, Jones M, Xia D, Marugan-Hernandez V, Blake D and Tomley F, 2021. Controlling the causative agents of coccidiosis in domestic chickens; an eye on the past and considerations for the future. *CABI Agriculture and Bioscience* 2(1): 37. <https://doi.org/10.1186/s43170-021-00056-5>
- Bafundo KW, Cervantes HM and Mathis GF, 2008. Sensitivity of *Eimeria* field isolates in the United States: responses of nicarbazin-containing anticoccidials. *Poultry Science* 87(9): 1760–1767. <https://doi.org/10.3382/ps.2008-00129>
- Bo R, Dai X, Huang J, Wei S, Liu M and Li J, 2020. Evaluation of optimum conditions for decoquinate nanoliposomes and their anticoccidial efficacy against diclazuril-resistant *Eimeria tenella* infections in broilers. *Veterinary Parasitology* 283: 109186. <https://doi.org/10.1016/j.vetpar.2020.109186>
- Boyko O, Shendryk L, Shaban O and Brygadyrenko V, 2021. Influence of essential oils on sporulation of *Eimeria magna* oocysts. *Annals of Parasitology* 67(1): 11–17. <https://doi.org/10.17420/ap6701.307>
- Bozkurt M, Ege G, Aysul N, Akşit H, Tüzün AE, Küçükylmaz K, Borum AE, Uygun M, Akşit D, Aypak S, Şimşek E, Seyrek K, Koçer B, Bintaş E and Orojpour A, 2016. Effect of anticoccidial monensin with oregano essential oil on broilers experimentally challenged with mixed *Eimeria* spp. *Poultry Science* 95(8): 1858–1868. <https://doi.org/10.3382/ps/pew077>
- Cha JO, Belal SA, Kim SJ and Shim KS, 2020. Quality traits, fatty acids, mineral content of meat and blood metabolites changes of broiler chickens after artificial infection with sporulated *Eimeria tenella* oocysts. *Italian Journal of Animal Science* 19(1): 1472–1481. <https://doi.org/10.1080/1828051X.2020.1848462>
- Chapman HD and Blake DP, 2022. Genetic selection of *Eimeria* parasites in the chicken for improvement of poultry health: implications for drug resistance and live vaccine development. *Avian Pathology* 51(6): 521–534. <https://doi.org/10.1080/03079457.2022.2117018>
- Chapman HD and Rathinam T, 2022. Focused review: The role of drug combinations for the control of coccidiosis in commercially reared chickens. *International Journal for Parasitology. Drugs and Drug Resistance* 18: 32–42. <https://doi.org/10.1016/j.ijpddr.2022.01.001>
- Da Costa MJ, Bafundo KW, Pesti GM, Kimminau EA and Cervantes HM, 2017. Performance and anticoccidial effects of nicarbazin-fed broilers reared at standard or reduced environmental temperatures. *Poultry Science* 96(6): 1615–1622. <https://doi.org/10.3382/ps/pew475>
- Dardi M, Pagès M, Syed B and Valenzuela L, 2018. Evaluation of the combined effect of probiotics and coccidia vaccine in coccidia-challenged broilers. Paper presented at 55th Symposium of the Spanish Branch of the WPSA (AECA), Madrid, Spain. <https://www.thepoultrysite.com/articles/evaluation-of-the-combined-effect-of-probiotics-and-coccidia-vaccine-in-coccidiachallenged-broilers>
- Dauguschies A, Gässlein U and Rommel M, 1998. Comparative efficacy of anticoccidials under the conditions of commercial broiler production and in battery trials. *Veterinary Parasitology* 76(3): 163–171.
- El-Ashram S, Abolhadid SM, Araf WM, Gadelhaq SM and Abdel-Razik ARH, 2019. Protective potential of diclazuril-treated oocysts against coccidiosis in layer chicks. *Veterinary Parasitology* 273: 105–111. <https://doi.org/10.1016/j.vetpar.2019.08.010>
- Elkomy A, Aboubakr M and Medhat Y, 2015. Anticoccidial efficacy of diclazuril on experimentally *Eimeria tenella* infected broiler chickens. *Benha Veterinary Medical Journal* 29(2): 23–28. <https://doi.org/10.21608/BVMJ.2015.31541>
- Farran T, Shaib H, Hakeem WG, Kaouk ZM and Harkous AA, 2020. Performance of *Eimeria*-challenged male broilers fed 2 ionophore–nicarbazin combinations. *Journal of Applied*

- Poultry Research 29(3): 684-691. <https://doi.org/10.1016/j.japr.2020.05.002>
- Flores RA, Nguyen BT, Cammayo PLT, Vo TC, Naw H, Ki S, Kim WH, Na BK and Min W, 2022. Epidemiological investigation and drug resistance of *Eimeria* species in Korean chicken farms. BMC Veterinary Research 1418(1): 277. <https://doi.org/10.1186/s12917-022-03369-3>
- Flores RA, Nguyen BT, Cammayo PLT, Vo TC, Naw H, Ki S, Kim WH, Na BK and Min W, 2022. Epidemiological investigation and drug resistance of *Eimeria* species in Korean chicken farms. BMC Veterinary Research 18: 277. <https://doi.org/10.1186/s12917-022-03369-3>
- Freitas FLC, 2014. Metabolic alterations in broiler chickens experimentally infected with sporulated oocysts of *Eimeria maxima*. Revista Brasileira de Parasitologia Veterinária 23 (3): 309-314.
- Gautier AE, Latorre JD, Matsler PL and Rochell SJ, 2020. Longitudinal Characterization of Coccidiosis Control Methods on Live Performance and Nutrient Utilization in Broilers. Frontiers in Veterinary Science 6: 468. <https://doi.org/10.3389/fvets.2019.00468>
- Glorieux M, Newman LJ, Wang YT, Herdt P, Hautekeur De J, Gussem M, De Christiaens I and Verbeke J, 2022. Sustainable coccidiosis control implications based on susceptibility of European *Eimeria* field isolates to Narasin + nicarbazin from farms using anticoccidial medication or coccidial vaccines. Journal of Applied Poultry Research 31(3): 100263. <https://doi.org/10.1016/j.japr.2022.100263>
- Hayajneh FMF, Abdelqader A, Alnimer MA, Abedal-Majed MA and Al-Khazaleh J, 2020. The role of high-grade Bentonite powder in coccidiosis and its effects on feed conversion ratio and blood parameters in broiler chicken. Polish Journal of Veterinary Sciences 23: 97-107. <https://doi.org/10.24425/pjvs.2020.132753>
- Huang J, Huang J, Husien HM, Peng W, Liu M, Bo R and Li J, 2022. Comparison of endogenous development, invasion ability and apoptotic features between diclazuril resistant and sensitive strains of *Eimeria tenella*. Veterinary Parasitology 305: 109719. <https://doi.org/10.1016/j.vetpar.2022.109719>
- Kawazoe U and Di Fabio J, 1994. Resistance to diclazuril in field isolates of *Eimeria* species obtained from commercial broiler flocks in Brazil. Avian Pathology 23: 305-311. <https://doi.org/10.1080/03079459408418998>
- Kawazoe U and Difabio J, 1994. Resistance to diclazuril in field isolates of *Eimeria* species obtained from commercial broiler flocks in Brazil. Avian Pathology 23: 305-311.
- Khater HF, Ziam H, Abbas A, Abbas RZ, Raza MA, Hussain K, Younis EZ, Radwan IT and Selim A, 2020. Avian coccidiosis: Recent advances in alternative control strategies and vaccine development. Agrobiological Records 1: 11-25. <https://doi.org/10.47278/journal.abr/2020.003>
- Künzel S, Borda-Molina D, Kraft R, Sommerfeld V, Kühn I, Camarinha-Silva A and Rodehutsord M, 2019. Impact of coccidiostat and phytase supplementation on gut microbiota composition and phytate degradation in broiler chickens. Animal Microbiome 1(1): 5. <https://doi.org/10.1186/s42523-019-0006-2>
- Kurkure NV, Kolte SW, Bhandarkar AG and Kalore DDR, 2006. Evaluation of herbal coccidiostat coxynil in broiler. Indian Journal of Experimental Biology 44: 740-744.
- Lan LH, Sun BB, Zuo BX, Chen XQ and Du AF, 2017. Prevalence and drug resistance of avian *Eimeria* species in broiler chicken farms of Zhejiang province. China. Poultry Science 196 (7): 2104-2109. <https://doi.org/10.3382/ps/pew499>
- Lee Y, Lu M and Lillehoj HS, 2022. Coccidiosis: Recent progress in host immunity and alternatives to antibiotic strategies. Vaccines 10: 215. <https://doi.org/10.3390/vaccines10020215>
- Lillehoj HS and Lee KW, 2012. Immune modulation of innate immunity as alternatives-to-antibiotics strategies to mitigate the use of drugs in poultry production. Poultry Science 91(6): 1286-1291. <https://doi.org/10.3382/ps.2012-02374>
- Lillehoj HS and Lillehoj EP, 2000. Avian coccidiosis. A review of acquired intestinal immunity and vaccination strategies. Avian Diseases 44(2): 408-425.
- Lima ALd, Barreto F, Rau RB, Silva GR, Lara LJC, Figueiredo TC, Assis DCS and Caçado SVC, 2017. Determination of the residue levels of nicarbazin and combination nicarbazin-Narasin in broiler chickens after oral administration. PLoS ONE 12(7): e0181755. <https://doi.org/10.1371/journal.pone.0181755>
- Mares MM, Al-Quraishy S, Abdel-Gaber R and Murshed M, 2023. Morphological and Molecular Characterization of *Eimeria* spp. Infecting Domestic Poultry *Gallus gallus* in Riyadh City, Saudi Arabia. Microorganisms 11(3): 795. <https://doi.org/10.3390/microorganisms11030795>
- Martins RR, Pereira AMPT, Silva LJG, Esteves A, Duarte SC, Freitas A and Pena A, 2023. Risk assessment of nine coccidiostats in commercial and home-raised eggs. Foods 12(6): 1225. <https://doi.org/10.3390/foods12061225>
- Martins RR, Silva LJG, Pereira AMPT, Esteves A, Duarte SC and Pena A, 2022. Coccidiostats and poultry: A comprehensive review and current legislation. Foods (Basel, Switzerland) 11(18): 2738. <https://doi.org/10.3390/foods11182738>
- Mesa C, Gómez-Osorio LM, López-Osorio S, Williams SM and Chaparro-Gutiérrez JJ, 2021. Survey of coccidia on commercial broiler farms in Colombia: frequency of *Eimeria* species, anticoccidial sensitivity, and histopathology. Poultry Science 100(8): 101239. <https://doi.org/10.1016/j.psj.2021.101239>
- Morris GM, Woods WG, Richards DG and Gasser RB, 2007. Investigating a persistent coccidiosis problem on a commercial broiler-breeder farm utilising PCR-coupled capillary electrophoresis. Parasitology Research 101 (3): 583-9. <https://doi.org/10.1007/s00436-007-0516-9>
- Obasi OL, Ifut OJ and Offiong EA, 2006. An outbreak of caecal coccidiosis in a broiler flock post Newcastle disease vaccination. Journal of Animal Veterinary Advances 5 (12): 1239-1241
- Oikeh I, Sakkas P, Blake DP and Kyriazakis I, 2019 Interactions between dietary calcium and phosphorus level, and vitamin D source on bone mineralization, performance, and intestinal morphology of coccidia-infected broilers. Poultry Science 98(11): 5679-5690. <https://doi.org/10.3382/ps/pez350>
- Peek HW and Landman WJM, 1996. Resistance to anticoccidial drugs of Dutch avian *Eimeria* spp. field isolates originating from 1996, 1999 and 2001. Avian Pathology 32(4): 391-401. <https://doi.org/10.1080/0307945031000121149>
- Raman M, Samsudeen S, Banu, Gomathinayagam S, Gopa D and Raj, 2011. Lesion scoring technique for assessing the virulence and lesion scoring technique for assessing the virulence and pathogenicity of Indian field isolates of avian *Eimeria* species. Veterinarski Arhiv 81(2): 259-271.
- Ruff MD and Danforth HD, 1996. Resistance of coccidian to medications. XX World's Poultry Congress, II, 427-430
- Salem HM, Salem MA, Soliman MM, Althobaiti SA, Khafaga AK, El-Tahan AM, El-Saadony MT and Attia MM, 2022. Parasitological and histopathological examination of Cocktail lovebirds infected with *Eimeria aratinga* (Apicomplexa: Eimeriidae). Poultry Science 101(5): 101781. <https://doi.org/10.1016/j.psj.2022.101781>
- Shirley MW, Smith AL and Tomley FM, 2005. The biology of avian *Eimeria* with an emphasis on their control by vaccination. Advanced Parasitology 60: 285-330.
- Stephen B, Rommel M, Dauschies A and Haberkorn A, 1997. Studies of resistance to anticoccidials in *Eimeria* field

- isolates and pure *Eimeria* strains. Veterinary Parasitology 69(1-2): 19-29. [https://doi.org/10.1016/s0304-4017\(96\)01096-5](https://doi.org/10.1016/s0304-4017(96)01096-5)
- Tan L, Li Y, Yang X, Ke Q, Lei W, Mughal MN, Fang R, Zhou Y, Shen B and Zhao J, 2017. Genetic diversity and drug sensitivity studies on *Eimeria tenella* field isolates from Hubei Province of China. Parasites and Vectors 10: 137. <https://doi.org/10.1186/s13071-017-2067-y>
- Taylor J, Walk C, Misiura M, Sorbara JB, Giannenas I and Kyriazakis I, 2022. Quantifying the effect of coccidiosis on broiler performance and infection outcomes in the presence and absence of control methods. Poultry Science 101: 101746. <https://doi.org/10.1016/j.psj.2022.101746>
- Thabet A, Alnassan AA, Dauschies A and Bangoura B, 2015. Combination of cell culture and qPCR to assess the efficacy of different anticoccidials on *Eimeria tenella* sporozoites. Parasitology Research 114: 2155–2163. <https://doi.org/10.1007/s00436-015-4404-4>
- Toledo GA, Almeida JD, Almeida KS and Freitas FL, 2011. Coccidiosis in broiler chickens raised in the Araguaína region, State of Tocantins. Revista Brasileira de Parasitologia Veterinaria 20(3): 249-52.
- Turk DE, 1981. Coccidial infections and iron absorption. Poultry Science 60(2): 323-326. <https://doi.org/10.3382/ps.0600323>
- Usman JG, Gadzama UN, Kwaghe AV and Madziga HA, 2011. Anticoccidial resistance in poultry: A review. New York Science Journal 4(8): 102-109.
- Vereecken M, Dehaeck B, Berge AC, Marien M, Geerinckx M and De Gussem K, 2020. Synergistic effect of a combination of nicarbazin and monensin against coccidiosis in the chicken caused by *Eimeria* spp. Avian Pathology 49(4): 389-393. <https://doi.org/10.1080/03079457.2020.1756226>
- Willems OW, Miller SP and Wood BJ, 2013. Aspects of selection for feed efficiency in meat producing poultry. World's Poultry Science Journal 69(1): 77-88. <https://doi.org/10.1017/S004393391300007X>