



The Emerging Topic of Cosmetic Medicine in Dromedary Camels

Mohamed Tharwat^{1,*} and Abdulla Al-Hawas²

¹Department of Veterinary Medicine, College of Agriculture and Veterinary Medicine, Qassim University, P.O. Box 6622, Buraidah, 51452, Saudi Arabia

²Al-Hawas Comprehensive Veterinary Clinics, Qassim, Mithnab 56634, Saudi Arabia

*Corresponding author: atieh@qu.edu.sa

Article History: 23-222

Received: 28-May-2023

Revised: 05-Jun-2023

Accepted: 09-Jun-2023

ABSTRACT

The camel festival beauty show is held annually in Saudi Arabia where camels are examined from different countries worldwide. Owing to the huge awards given to the owners of the most beautiful camels in this contest, some camel owners therefore try to alter the look of their animals through different cosmetic methods of tampering. Current review is written to focus on the topic of cosmetics in dromedary camels. It will especially focus firstly on beauty standards in camels followed by tampering in camels and methods and materials used. It will also discuss the methods for detection of tampering, especially clinical detection by ultrasound and thermography. Only experienced people can detect tampering in camels. Because there are new ways to be discovered daily for tampering with camels, discovering these methods constitute a great challenge even for experienced practitioners in this field. The visual examination is one of the most important ways to detect tampering in camels, which is later confirmed by a clinical test such as ultrasound and thermal camera examination, or by laboratory tests such as estimating the level of hormones in the blood. In recent years, cosmetic medicine has rapidly grown in camels in Saudi Arabia. Finally, it can be said that the organizers of the camel beauty festivals must set strict controls in order to combat tampering with this creature, prevent its harm, and provide a full and equal opportunity for all competitors.

Key words: Animals, Animal health, Diagnostic imaging, Infrared devices, Diagnosis.

INTRODUCTION

The camel has a vital role in human life, especially in desert areas, because of its multi-purpose role and great ability to adapt to difficult weather conditions, despite its enormous economic, cultural and biological importance. Camels gained their importance as it can live and reproduce under severe harsh climatic conditions of heat and drought which are not suitable for the survival of other domestic animals (Muyldermans 2013). They constitute a major part in the life way of different organizations, particularly those in arid areas in the Middle East and the Arabian countries (Kaskous 2016). The total camel world population is about 29 million, of which around 95% are one-humped or dromedary (Sikkema et al. 2019).

Eight camel breeds are well-known in Saudi Arabia: (1) Waddah characterized by a white coat color, (2) Majaheem with a black color, (3) Homor with a red color (4) Sofor with a yellow-brown color, (5) Shaele breed with a grey coat color, (6) Shageh characterized by a small head and short and large neck and narrow chest, (7) Asail is a racing camel characterized by a fine head with flat forehead, and the (8)

is the Saheli camels that are living along the Red Sea coast and has a characteristic red color (Fig. 1).

In recent years, camel beauty festivals are periodically organized in Saudi Arabia where huge prizes are awarded. Thus, cosmetic medicine in camels is currently rampant in Saudi Arabia (Tharwat et al. 2012a,b; Tharwat and Al-Hawas 2021; Tharwat and Al-Hawas 2023). The review will focus on 1; the beauty aspects of camels, 2; the motives for the increase in cosmetic medicine in camels in recent years, 3; the scourge of tampering in camels and the different methods for performing it, 4; hormonal injections and their natural values in females and males, and the interpretation of laboratory results of hormonal injections and side effects of hormonal injections, 5; materials used in tampering in camels, and finally 6; methods for detecting tampering in camels

Beauty Standards in Camels

When you hear of beauty pageants, you probably think of women and men competing to show off their good looks. However, it seems that the cosmetic fever is no longer confined to humans, as camels have recently entered the line,




Fig. 1: Most common breeds of camels in Saudi Arabia. Waddah (or Maghatir) or white camels (a), Majaheem or black camels (b), Homor (or Hamrah) or camels with a red coat (c), Sofor (or Safrah) camels have a yellow brown coat color (d), Shaele camels have a grey coat color going sometimes to brown-red (e), Shageh camels that have a small-head with short and thick neck and narrow chest (f), Asail camels with yellow to brown coat color (g), and Saheli camels that has a red coat color (h).

fter the emergence of what is known as camel beauty and the competitions for beauty, which depend on standards and quantities for beauty competition in it. When a "camel" is described as "beautiful", this description is based on a set of standards known to specialists. Also, the beautiful camel, with its stature and height, is unmistakable in the eyes of beauty lovers and seekers. As for the reason that forced camel owners to undergo cosmetic surgery, it can be said that most of the cosmetic operations (or rather, changing the features of the animal) are for marketing purposes in order to comply with the beauty standards known to camel owners, and then sell those camels at more expensive prices than their real price.

Camels have many places of beauty that distinguish one from the other and cause a discrepancy in their prices. There are several criteria by which camels are won, and also raise the price of camels, which are features that distinguish camels from each other. One of the most prominent specifications of beauty among camels is that their beauty is natural and not artificial, with its division according to their color and breed. As for the hair, it must be curly in order to complete the specifications of beauty. Half of the beauty of the camel lies in the head, starting from the ears, eyes, nose, the shape of the lips, their drooping, and many details in the head, while the rest of the beauty measures are distributed on the body of the camel, its color, height, foot and other parts of the camel. Therefore, it can be said that plastic surgery is mostly done

on the lips of camels, and the ears are surgical operations, which distinguishes those areas with beauty and good appearance. This is a cause for pride among camel owners, as camels are distinguished by their natural beauty, and their owners sing them in all forums for their rarities, such as those with blue eyes or white stripes, and their prices exceed millions of dollars (Tharwat and Al-Hawas 2021; Tharwat and Al-Hawas 2023).

In the head, the lips should be long and must cover the teeth, and the size of the head must be large. The shape and size of the eyes are one of the basics of camel beauty, and the longer the eyelashes, the greater the chance of winning, and the nose should be long and wide. The beauty of the head varies between the colors of the camels in the ear only. So it is preferable that the ears of the Majahatir are short and pricked backwards and the Majaheem's ears are preferably long and advanced. The beauty of camels also lies in their necks, so it is desirable that the neck be long and thin, and moving forward in height, provided that its leg bones are large and long. Also, the category of Majaheem differs from the Mughatir in the foot, as the Majahihim prefer to have a large foot, while the Mughatir prefer small, round ones. It is preferable in the Majaheem to have leg curved inward, and the tail is long and broad, while in Maghatire the tail is preferred to be short. One of the beautiful characteristics of camels is that the hump should lie to the back near the tail root (Fig. 2) (Tharwat and Al-Hawas 2021; Tharwat et al. 2021a,b; Tharwat and Al-Hawas 2023).



Fig. 2: Some beauty standard in camels. The lips are long and cover the teeth, and the head is large. The eyelashes are long, and the nose is long and wide. The ears are also short and pricked backwards (a). The neck is long and thin, and moving forward in height and the leg bones are large and long (b). The hump lies to the back of the camel near the root of the tail (c).

Motives Behind the Increase in Plastic Surgeries in Camels in Last Years

The camel beauty shows are being held in the Arabian Peninsula, especially in the Kingdom of Saudi Arabia, United Arab Emirates and Kuwait. In the Kingdom of Saudi Arabia, the camel beauty show is held annually where camels (the vast majority are females) are presented from different countries all over the world with total prizes of almost 32 million USD during the festival. Therefore, some camel holders try to enhance the change the look of

their camels by various injections and stretching of the lips (Tharwat and Al-Hawas, 2021; Tharwat et al., 2021a,b; Tharwat and Al-Hawas 2023).

Tampering in Camels

Owing to the very high awards given to the holders of the winners' camels, some people try to increase the normal look of their animals even through artificial procedures. Unskilled peoples or unqualified holders use these ways. Different procedures of tampering are well-known to be used in dromedary camels (Tharwat and Al-Hawas, 2021; Tharwat et al., 2021a,b; Tharwat and Al-Hawas 2023). Fasten both lips with a rubbery belt and then pulling them outward drooping of lips is one of these methods (Fig. 3). Squeezing the lips using a segment of a plastic material to stimulate enlargements of the lips is another method. A very famous method is by stretching and daily massage of both upper and lower lips resulting in drooping of both lips (Fig. 4). Employing topical or regional anaesthetics, to encourage laxity in the lips is one of the methods of tampering in camels, as it leads to the drooping of the lower lip and changing the appearance of the camel (Tharwat and Al-Hawas 2021).

Different abnormal procedures are usually applied, including trimming the ears to make them shorter (Fig. 5); cosmetic injections such as filler materials into the lips (Fig. 6) and nose region, and Botox injections to decrease nerve indicatives and thus induce relaxation of the lips and producing the attractive pout appearance. Botox (botulinum toxin) injection is one of the most injected substances into camels in a trial to make their pouts look more alluring. Using the Botox for the lips, nose, and even the jaw makes the head larger. Another method of tampering is by applying pigmentation to alter the color class for the show; and eventually applying various materials as oils, sugar, starch that are banned by the medical committee (Tharwat and Al-Hawas 2021).

Hormonal Injection and Side Effects

Few camel owners may resort to injecting hormones into their camels at young ages in order to change the general shape of the animal, such as stimulating growth, enlarging the head and bones and increasing muscle mass faster. Among these hormones, the most famous of which is testosterone and growth hormone (GH), in addition to estrogen and progesterone hormones, which are less used. Injecting these hormones has clear symptoms on camels that are well known, including, for example, but not limited to, the large head and neck, the length of the bones, the large size of muscles, the enlargement of the clitoris and the high rate of female infertility (Tharwat et al. 2021b).

The androgenic-anabolic steroids (AAS) are artificial by-products of the testosterone hormone and are widely used among athletes for improving performance and cosmetic caused. Several reports describing the complications of these materials have been documented (Friedl 2000). Effects of AAS include the development of male distinguishing such as muscular strength, voice thickening and hair evolution as well as activating protein formation and decreasing protein collapse (Kochakian 1993; Wilson 1996). Changes in libido changes and infertility are remarkable influences on the genital system (Christou et al. 2017). Major side effects on the psyche and



Fig. 3: Enlargement, protrusion and stretched lips in a female camel due to stretching the lips and then pulling them outward.



Fig. 6: Enlargement of the upper and lower lips in a female camel due to injection of a filler material.



Fig. 4: Drooping of upper and lower lips in a female camel due to continuous stretching and daily massage.



Fig. 5: Clipping or trimming the ears (arrow) in a female camel in a trial to make the ears perkier.

behavior have also been reported (Medras et al. 2018). Side-effects of AAS usage in females may include various signs such as disturbances in period or even severe harmful actions like tachyarrhythmia (Huang and Basaria 2018).

The function of the GH is to help stimulate the development of new tissue. Therefore, in young growing animals, the GH will be found at higher standards. Following, the levels of GH will decrease greatly once the adulthood stage is reached. If the GH levels are too low, a range of effects will occur according to the age of the animal. The veterinarian may inject the animal with GH to correct this problem. Reports have also documented that anabolic action of hormones, such as GH, insulin-like growth factor may counter the catabolic action linked with cachexia in human patients (Kotler 2000; Wang et al. 2000).

Normal Values of Testosterone and Growth Hormones Levels in Camels

The normal values of testosterone and GH levels in female camels, minimum and maximum values, alongside the 25th, 50th, 75th, 95th and 99th percentiles are shown in Table 1. Compared to a value of 51 ± 9 pg/mL in female camels aged 6 to 15 months, the testosterone value is 52 ± 7 pg/mL in camels aged over 15 months until 10 years of age (Tharwat et al. 2021b). The minimum and maximum levels in the first group were 34 and 75 pg/mL, while the minimum and maximum levels in the second group are 37 and 66 pg/mL, respectively. There is no statistically significant difference when comparing testosterone values in both groups. Compared to a value of 2.7 ± 0.4 ng/mL in camels aged 6 to 15 months, the GH value is 2.2 ± 0.3 ng/mL in camels aged over 15 months until 10 years of age. The minimum and maximum levels in the first group are 1.9 and 4.3 ng/mL, while the minimum and maximum levels in the second group are 1.6 and 2.9 ng/mL, respectively. There is a highly statistically significant difference when comparing GH values in both groups (Tharwat et al. 2021b). The normal values of testosterone and GH levels in male camels, minimum and maximum values, alongside the 25th, 50th, 75th, 95th and 99th percentiles are shown in Table 2 and Table 3 (personal unpublished data).

In female camels, the minimum and maximum levels of testosterone hormone levels are 34 and 75 pg/mL, respectively. In addition, the minimum and maximum levels of GH levels are 1.9 and 4.3 ng/mL, respectively. Therefore, female camels having values of testosterone over 75 pg/mL or GH values over 4.3 ng/mL should be

Table 1: Testosterone and growth hormones levels in camels aged 6-15 months and in those over 15 months up to 10 years (n=55) (Tharwat et al. 2021b)

Parameter	Testosterone (pg/mL)		Growth hormone (ng/mL)	
	06 - 15 m	15m - 10y	06-15 month	15m-10y
Mean \pm SD	51 \pm 9 ^a	52 \pm 7 ^a	2.7 \pm 0.4 ^a	2.2 \pm 0.3 ^b
Minimum	34	37	1.9	1.6
Maximum	75	66	4.3	2.9
0.25% Percentile	45	46	2.4	2.0
0.50% Percentile	50	51	2.7	2.2
0.75% Percentile	55	57	2.9	2.3
0.95% Percentile	65	62	3.4	2.6
0.99% Percentile	71	64	3.9	2.9

Table 2: Testosterone hormone level in male camels aged 1 to 4 years (n=48) (personal unpublished data)

Parameter	Testosterone (pg/mL)			
	4 years	3 years	2 years	1 year
Mean \pm SD	46 \pm 8 ^a	43 \pm 6 ^a	50 \pm 10 ^a	48 \pm 9 ^b
Minimum	28	34	34	34
Maximum	64	49	65	71
0.25% Percentile	42	40	43	41
0.50% Percentile	46	43	52	45
0.75% Percentile	50	48	55	53
0.95% Percentile	55	49	65	66
0.99% Percentile	62	49	65	71

Table 3: Growth hormone level in male camels aged 1 to 4 years (n=48) (personal unpublished data)

Parameter	Growth hormone (ng/mL)			
	4 years	3 years	2 years	1 year
Mean \pm SD	2.4 \pm 0.2 ^a	2.6 \pm 0.3 ^a	2.5 \pm 0.3 ^a	2.4 \pm 0.3 ^b
Minimum	2.1	2	2.1	1.9
Maximum	2.9	3	3.2	3.1
0.25% Percentile	2.2	2.475	2.3	2.2
0.50% Percentile	2.3	2.7	2.4	2.4
0.75% Percentile	2.5	2.7	2.575	2.5
0.95% Percentile	2.79	2.925	3.02	2.8
0.99% Percentile	2.879	2.985	3.164	3.054

thoroughly examined to ensure if these animals are injected with testosterone or GH. On the other side, the minimum and maximum levels of testosterone hormone levels in males (1-4 years of age) are 28 and 71pg/mL, respectively. In addition, the minimum and maximum levels of GH levels in males (1-4 years of age) are 2.0 and 3.2ng/mL, respectively. Therefore, male camels of 1-4 years old having values of testosterone over 71pg/mL or GH values over 3.2ng/mL should be thoroughly examined to ensure if these animals are injected with testosterone or GH (Tharwat et al. 2021b).

Side Effects of Hormonal Overdosing in Camels

Hormones were created to treat some health problems that come on animals due to the disruption of their own formation in the body. In human medicine, the misuse or large doses of testosterone and GH therapies have several undesirable consequences (Ohlander et al. 2018; Salzano et al. 2019; Pinkerton et al. 2021; Twitchell et al. 2021; Wang and Swerdloff 2022). Similar, the misuse of these hormones in camels leads to the emergence of abnormal symptoms (Tharwat et al. 2021b). By injecting testosterone or GH, the general shape of the animal grows hugely, and the length of the bones differs from their normal growth. These changes of course are acquired but not transmitted to

the neonates. Hormonal injections lead to effects produced on the outside of the body and effects inside the body. The udder is larger than normal, even at young ages. Prominence and increased growth of the clitoris is evident (Fig. 7). Other effects of hormone injections include an increase or decrease in sexual desire, animal isolation, facial swelling, change of voice, retardation of growth in young cases, skin rash and various skin lesions (Fig. 8). Clinically, the behavior of female camels usually changes to become more like a male, and the masculine characteristics are very prominent and noticeable, especially if they are used early in the stages of growth. As a result, the dulla is enlarged and protruded in injected females (Fig. 9).

Materials used in Tampering of Camels and their Misuse

In humans, plastic surgery is a very developing area (Rohrich 2021; Seyidova et al. 2021; Stuzin and Rohrich 2021). This cosmetic medicine may include a least invasive approach using resorbable fillers such as the widely used hyaluronic acid (HA) products (Fagien et al. 2019; Wongprasert et al. 2022). These fillers are considered external products widely used by human surgeons to reduce the normal influence of senility, for example the formation of wrinkled skin, or for lip and cheek increment. Classification of filler materials includes degradable materials as HA and non-degradable materials as silicone (Diaz 2019; Ashinoff 2000; Klein 2001). Fillers can also be divided according to the biodegradation characteristics as quick absorbable within eleven months, delayed absorbable within twenty-four months, and constant (Smith 2008; Mundada 2017).

In dromedary camels, there has been a rapidly growing use of fillers by prohibited and unskilled peoples that leads to different undesirable consequences that are when applying materials that are not permitted for use in the medical field. Five principles consequences are discovered: (1) complications at the injection site as redness, dropsy, suffering and contusions (2) consequences of unsuitable injection techniques as the development of sensible nodes, apparent fillers, high - or low repair (3) sensitivity response (4) vascular side effects due to unwitting vascular injection of a filler material and (5) various microorganism contagions (Schutz et al. 2012; Shahrabi-Farahani et al. 2014).

Detection of Tampering in Camel

Only experienced people can detect tampering in camels. There are many ways that an expert can detect tampering in camels. And because there are new ways to be discovered daily for tampering with camels, discovering these methods constitute a great challenge even for experienced practitioners in this field. The visual examination is one of the most important ways to detect tampering in camels, which is later confirmed by a clinical test such as ultrasound and thermal camera examination, or by laboratory tests such as estimating the level of hormones in the blood. Tampering is usually detected either by clinical examination methods, ultrasound examination or by thermography (Tharwat and Al-Hawas, 2021; Tharwat et al., 2021a,b; Tharwat and Al-Hawas 2023).

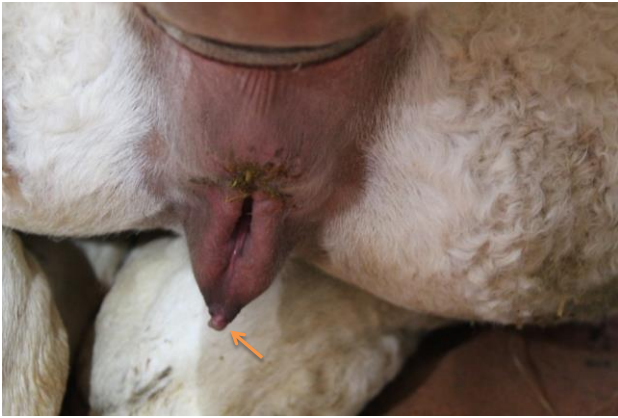


Fig. 7: Vulval edema and prominence and increased growth of the clitoris (arrow) in a 6-month age female camels as a result of repeated testosterone hormone injection.



Fig. 8: Skin rash and granulomatous skin lesions on the neck region in a female camel due to repeated hormone injection.

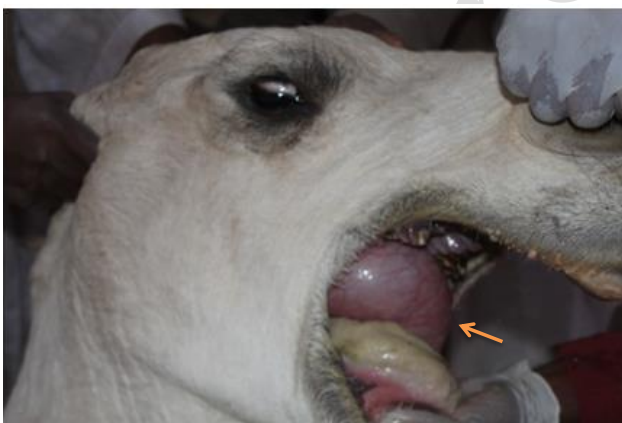


Fig. 9: Pronounced enlargement and protrusion of the dulla (arrow) in a female camel due to repeated hormone injection.

Ultrasonography was proved to be effective in examining camels either in healthy (El-Tookhy and Tharwat 2012; Tharwat et al. 2012a,b,c; Tharwat 2013a; Tharwat 2023) or diseased (Tharwat et al. 2012d,e; Tharwat 2013b; Tharwat, 2019; Tharwat 2020a,b,c; Tharwat 2021a,b; Tharwat and El-Tookhy 2021; Tharwat 2023) camels. Sonography of dromedary camels supposed to lip fillers is a beneficial methodology that can carefully

detect an injected material and further mark the site and magnitude of skin residues. By using ultrasound in healthy camels, the normal dermis appears hyperechoic which is readily distinguished from the low echoic appearing subcutaneous tissue (Tharwat and Al-Hawas 2021). It is also recognized that the application of fillers, even if permitted by the USFDA can generate some complications (Bailey et al. 2001; Schutz et al. 2012; Urdiales-Gálvez et al. 2018; Kassir et al. 2020; Trinh et al. 2022).

Infrared thermography (IRT) is an indirect non-harmful diagnostic imaging, is strongly practical and shows promise for detecting lesions such as injected or stretched lips in camel beauty pageants. A combination of IRT with clinical and ultrasonographic examinations would be helpful for detecting such pathology. Abnormalities of the injected lips include swelling, hardness of the lip tips and the presence of multiple and hard nodules. When treated by IRT, the mucus membrane of the elongated lips appears lighter and more diverse versus the darker and homogenous pattern in the non-stretched lips. When pressure is on the stretched lips, more saliva comes out compared to the healthy lips in the healthy camel (Tharwat et al. 2021a; Tharwat and Al-Hawas 2023).

Conclusions

In recent years, plastic surgery is a fast-developing area in camels in Saudi Arabia. Huge awards were given to the owners of the most beautiful camels in this contest. Some camel owners therefore try to alter the look of their animals through different cosmetic methods. To the authors' knowledge, this is the first review that focuses on this emerging topic in camel medicine all over the world. Beauty standards in camels are described in detail in this review article. The topic of tampering in camels and the methods and materials used are investigated fully. The methods for detection of tampering, especially clinical detection by ultrasound and thermography also discussed. In the end, it can be said that this great heritage in the Kingdom of Saudi Arabia must be preserved, by all available means and punished by anyone who tries to harm and tamper with it in any way.

Conflicts of Interest

The authors declare no conflict of interest related to this review article.

Acknowledgments

The authors extend their appreciation to the Deputyship for Research & Innovation, Ministry of Education, Saudi Arabia for funding this research work through the project number (QU-IF-2-1-1-26881). The authors also thank Qassim University for technical support.

REFERENCES

- Ashinoff R, 2000. Overview: Soft tissue augmentation. *Clinics in Plastic Surgery* 27: 479-87.
- Bailey SH, Cohen JL and Kenkel JM, 2011. Etiology, prevention, and treatment of dermal filler complications. *Aesthetic Surgery Journal* 31: 110-121. <https://doi.org/10.1177/1090820X10391083>
- Christou MA, Christou PA, Markozannes G, Tsatsoulis A, Mastorakos G and Tigas S, 2017. Effects of anabolic androgenic steroids on the reproductive system of athletes

- and recreational users: A systematic review and meta-analysis. *Sports Medicine* 47: 1869-1883. <https://doi.org/10.1007/s40279-017-0709-z>
- Diaz CPG, 2019. High resolution ultrasound of soft tissues for characterization of fillers and its complications. *Revista Colombiana de Radiologica* 30: 5064-5068.
- El-Tookhy O and Tharwat M, 2012. Clinical and ultrasonographic findings of some ocular affections in dromedary camels. *Journal of Camel Practice and Research* 19: 183-191.
- Fagien S, Bertucci V, Von Grote E and Mashburn JH, 2019. Rheologic and physicochemical properties used to differentiate injectable hyaluronic acid filler products. *Plastic and Reconstructive Surgery* 143: 707e-720e. <https://doi.org/10.1097/PRS.0000000000005429>
- Friedl KE, 2000. Effects of anabolic steroids on physical health. In: *Anabolic steroids in sport and exercise*. Yesalis CE, editor. 2nd Ed. Champaign (IL): Human Kinetics, pp: 175–224.
- Huang G and Basaria S, 2018. Do anabolic-androgenic steroids have performance-enhancing effects in female athletes? *Molecular and Cellular Endocrinology* 464: 56-64. <https://doi.org/10.1016/j.mce.2017.07.010>
- Kaskous S, 2016. Importance of camel's milk for human health. *Emirates Journal of Food and Agriculture (EJFA)* 28: 158–163. <https://doi.org/10.9755/ejfa.2015-05-296>
- Kassir M, Gupta M, Galadari H, Kroumpouzou G, Katsambas A, Lotti T, Vojvodic A, Grabbe S, Juchems E and Goldust M, 2020. Complications of botulinum toxin and fillers: A narrative review. *Journal of Cosmetic Dermatology* 19: 570-573. <https://doi.org/10.1111/jocd.13266>
- Klein AW, 2001. Collagen and other injectables of the skin. *Dermatologic Clinics* 19: 491-508. [https://doi.org/10.1016/s0733-8635\(05\)70290-4](https://doi.org/10.1016/s0733-8635(05)70290-4)
- Kochakian CD, 1993. History, chemistry and pharmacodynamics of anabolic-androgenic steroids. *Wiener Medizinische Wochenschrift* 143: 359–363.
- Kotler DP, 2000. Cachexia. *Annals of Internal Medicine* 133: 622–634. <https://doi.org/10.7326/0003-4819-133-8-200010170-00015>
- Medras M, Brona A and Józkw P, 2018. The Central Effects of Androgenic-anabolic Steroid Use. *Journal of Addiction Medicine* 12: 184-192. <https://doi.org/10.1097/ADM.0000000000000395>
- Mundada P, Kohler R, Boudabbous S, Toutous Trelu L, Platon A and Becker M, 2017. Injectable facial fillers: Imaging features, complications and diagnostic pitfalls at MRI and PET CT. *Insights Imaging* 8: 557-572. <https://doi.org/10.1007/s13244-017-0575-0>
- Muyldermans S, 2013. Nano bodies: natural single domain antibodies. *Annual Review of Biochemistry* 82: 775–797. <https://doi.org/10.1146/annurev-biochem-063011-092449>
- Ohlander SJ, Varghese B and Pastuszak AW, 2018. Erythrocytosis following testosterone therapy. *Sexual Medicine Reviews* 6: 77-85. <https://doi.org/10.1016/j.sxmr.2017.04.001>
- Pinkerton JV, Blackman I, Conner EA and Kaunitz AM, 2021. Risks of testosterone for postmenopausal women. *Endocrinology and Metabolism Clinics of North America* 50: 139-150. <https://doi.org/10.1016/j.ecl.2020.10.007>
- Rohrich RJ, 2021. Plastic Surgery: Staying inside the Lines. *Plastic and Reconstructive Surgery* 148: 18S-19S. <https://doi.org/10.1097/01.prs.0000794784.09726.a7>
- Salzano A, Marra AM, Arcopinto M, D'Assante R, Triggiani V, Coscioni E, Pasquali D, Rengo G, Suzuki T, Bossone E and Cittadini A, 2019. Combined effects of growth hormone and testosterone replacement treatment in heart failure. *ESC Heart Failure* 6: 1216-1221. <https://doi.org/10.1002/ehf2.12520>
- Schutz P, Ibrahim HH, Hussain SS, Ali TS, El-Bassuoni K and Thomas J, 2012. Infected facial tissue fillers: Case series and review of the literature. *Journal of Oral and Maxillofacial Surgery* 70: 2403-2412. <https://doi.org/10.1016/j.joms.2011.11.014>
- Seyidova N, Chen AD, Lee J, Alnaeem H, Grover R and Lin SJ, 2021. Advanced practice providers in plastic surgery. *Plastic and Reconstructive Surgery* 147: 862e-871e. <https://doi.org/10.1097/PRS.00000000000007877>
- Shahrabi-Farahani S, Lerman MA, Noonan V, Kabani S and Woo SB, 2014. Granulomatous foreign body reaction to dermal cosmetic fillers with intraoral migration. *Oral Surgery, Oral Medicine, Oral Pathology and Oral Radiology* 117: 105-110. <https://doi.org/10.1016/j.oooo.2013.10.008>
- Sikkema RS, Farag EABA, Islam M, Atta M, Reusken CBEM, Al-Hajri MM and Koopmans M. PG, 2019. Global status of Middle East respiratory syndrome coronavirus in dromedary camels: a systematic review. *Epidemiology and Infection* 147: e84–e84. <https://doi.org/10.1017/S095026881800345X>
- Smith KC, 2008. Reversible vs. nonreversible fillers in facial aesthetics: concerns and considerations. *Dermatology Online Journal* 14: 3.
- Stuzin JM and Rohrich RJ, 2021. Plastic and Reconstructive Surgery and the Evolution of Cosmetic Surgery Education. *Plastic and Reconstructive Surgery* 147: 783-788. <https://doi.org/10.1097/PRS.00000000000007697>
- Tharwat M, Al-Sobayil F, Ali A and Buczinski S, 2012a. Echocardiography of the normal camel (*Camelus dromedarius*) heart: technique and cardiac dimensions. *BMC Veterinary Research* 8: 130. <https://doi.org/10.1186/1746-6148-8-130>
- Tharwat M, Al-Sobayil F, Ali A and Buczinski S, 2012b. Transabdominal ultrasonographic appearance of the gastrointestinal viscera of healthy camels (*Camelus dromedarius*). *Research in Veterinary Science* 93: 1015–1020. <https://doi.org/10.1016/j.rvsc.2011.12.003>
- Tharwat M, Al-Sobayil F, Ali A and Buczinski S, 2012c. Ultrasonography of the liver and kidneys of healthy camels (*Camelus dromedarius*). *Canadian Veterinary Journal* 53: 1273–1278.
- Tharwat M, Al-Sobayil F, Ali A and Buczinski S, 2012d. Ultrasonographic evaluation of abdominal distension in 52 camels (*Camelus dromedarius*). *Research in Veterinary Science* 93: 448–456. <https://doi.org/10.1016/j.rvsc.2011.07.009>
- Tharwat M, Al-Sobayil F, Ali A, Hashad M and Buczinski S, 2012e. Clinical, ultrasonographic, and pathologic findings in 70 camels (*Camelus dromedarius*) with Johnes's disease. *Canadian Veterinary Journal* 53: 543–548.
- Tharwat M, 2013a. Ultrasonography of the lungs and pleura in healthy camels (*Camelus dromedarius*). *Acta Veterinaria Hungarica* 61: 309–318. <https://doi.org/10.1556/AVet.2013.019>
- Tharwat M, 2013b. Ultrasonographic findings in camels (*Camelus dromedarius*) with trypanosomiasis. *Journal of Camel Practice and Research* 20: 283-287.
- Tharwat M, 2019. Chronic peritonitis in dromedary camels: clinical, hematobiochemical, ultrasonographic and pathologic findings. *Journal of Camel Practice and Research* 26: 169-172. <https://doi.org/10.5958/22778934.2019.00026.2>
- Tharwat M, 2020a. Ultrasonography of the abdomen in healthy and diseased camels (*Camelus dromedaries*). *Journal of Applied Animal Research* 48: 300-312. <https://doi.org/10.1080/09712119.2020.1788035>
- Tharwat M, 2020b. Ultrasonography of the liver in healthy and diseased camels (*Camelus dromedaries*). *Journal of Veterinary Medical Science* 82: 399–407. <https://doi.org/10.1292/jvms.19-0690>
- Tharwat M, 2020c. Ultrasonography of the kidneys in healthy and diseased camels (*Camelus dromedaries*). *Veterinary Medicine International* 2020: 7814927. <https://doi.org/10.1155/2020/7814927>

- Tharwat M and Al-Hawas A, 2021. Ultrasound detection of cosmic filler injection of lips in camel beauty pageants: first report in veterinary medicine. *Tropical Animal Health and Production* 53: 53. <https://doi.org/10.1007/s11250-020-02551-9>
- Tharwat M and El-Tookhy O, 2021. Ocular ultrasonography in healthy and diseased camels (*Camelus dromedaries*). *Journal of Camel Practice and Research* 28: 185-190.
- Tharwat M, Al-Hawas A and Albotti Y, 2021a. Infrared thermography in healthy dromedary camels and its feasibility in injected and stretched lips in camel beauty pageants. *Journal of Camel Practice and Research* 28: 355-359. <https://doi.org/10.5958/2277-8934.2021.00054.0>
- Tharwat M, Al-Hawas A and Aldhubayi A, 2021b. Testosterone and growth hormone levels in female dromedary camels. *Journal of Camel Practice and Research* 28: 373-376. <https://doi.org/10.5958/2277-8934.2021.00057.6>
- Tharwat M, 2021a. Obstructive urolithiasis in dromedary camels: clinical, ultrasonographic and postmortem findings. *Journal of Camel Practice and Research* 28: 85-93. <https://doi.org/10.5958/2277-8934.2021.00013.8>
- Tharwat M, 2021b. Ultrasonography of the thorax in healthy and diseased camels (*Camelus dromedaries*) – a mini-review. *Journal of Camel Practice and Research* 28: 313-318. <https://doi.org/10.5958/2277-8934.2021.00048.5>
- Tharwat M, 2023. Fundamentals of diagnostic ultrasound in dromedary camel medicine. *Intentional Journal of Veterinary Science*. <https://doi.org/10.47278/journal.ijvs/2023.057>
- Tharwat M and Al-Hawas A, 2023. Infrared thermography in healthy Arabian camels (*Camelus dromedarius*). *Intentional Journal of Veterinary Science* 12(5): In press. <https://doi.org/10.47278/journal.ijvs/2023.027>
- Trinh LN, McGuigan KC and Gupta A, 2022. Delayed Complications following Dermal Filler for Tear Trough Augmentation: A Systematic Review. *Facial Plastic Surgery* 38: 250-259. <https://doi.org/10.1055/s-0041-1736390>
- Twitchell DK, Pastuszak AW and Khera M, 2021. Controversies in testosterone therapy. *Sexual Medicine Reviews* 9: 149-159. <https://doi.org/10.1016/j.sxmr.2020.09.004>
- Urdiales-Gálvez F, Delgado NE, Figueiredo V, Lajo-Plaza JV, Mira M, Moreno A, Ortíz-Martí F, Del Río-Reyes R, Romero-Álvarez N, Del Cueto SR, Segurado MA and Rebenaque CV, 2018. Treatment of soft tissue filler complications: Expert consensus recommendations. *Aesthetic Plastic Surgery* 42: 498-510. <https://doi.org/10.1007/s00266-017-1063-0>
- Wang C and Swerdloff RS, 2022. Testosterone replacement therapy in hypogonadal men. *Endocrinology and Metabolism Clinics of North America* 51: 77-98. <https://doi.org/10.1016/j.ecl.2021.11.005>
- Wang W, Iresjo BM, Karlsson L and Svanberg E, 2000. Provision of rhIGF-I/IGFBP-3 complex attenuated development of cancer cachexia in an experimental tumor model. *Clinical Nutrition* 19: 127-132. <https://doi.org/10.1054/clnu.1999.0090>
- Wilson J, 1996. Androgens. In: Hardman J, Limbird L, editors. Goodman and Gilman's the pharmacological basis of therapeutictherapeutics. 9th Eed. New York: McGraw-Hill, pp.: 1441-1457.
- Wongprasert P, Dreiss CA and Murray G, 2022. Evaluating hyaluronic acid dermal fillers: A critique of current characterization methods. *Dermatologic Therapy* 35: e15453. <https://doi.org/10.1111/dth.15453>