



Research Article

Evaluation of Hepcidin Level and Clinico-Pathological Modifications in Canine Parvovirus Enteritis

Noha Y Salem^{1*}, Shima G Yehia¹, Heba S Farag² and Soliman M Soliman²

¹Department of Medicine and Infectious Diseases, Internal Medicine, Faculty of Veterinary Medicine, Cairo University, Egypt; ²Department of Medicine and Infectious Diseases, Infectious Diseases, Faculty of Veterinary Medicine, Cairo University, Egypt

*Corresponding author: nemovet2011@gmail.com

Article History: Received: April 22, 2018 Revised: June 03, 2018 Accepted: June 23, 2018

ABSTRACT

Canine parvovirus enteritis (CPV) is one of foremost reasons of vomiting and diarrhea in puppies with consequential alterations in homeostasis; anemia is one of these major changes. This investigation aimed to study alterations in Hepcidin and clinic-pathologic parameters in CPV infected puppies. This investigation carried out thirteen puppies with CPV enteritis and five clinically healthy puppies were enrolled as control with total number of 18 puppies. Upon admission, clinical signs were recorded and rapid in-clinic IC test kit for detection of CPV Ag in feces. Blood samples were used to determine hematologic and biochemical alterations along with hepcidin level. Vomiting and diarrhea were the main recorded clinical signs. Significant reduction in erythrogram and leucogram were recorded in CPV infected puppies. A reduction in Total Protein and albumin accompanied with elevation in triglycerides and Blood Urea Nitrogen were recorded. Significant elevation in serum hepcidin values in CPV enteritis when compared to control data was recorded. Depending on obtained results, CPV enteritis is associated with elevation in hepcidin level, anemia, reduction in leucocytes and elevation in triglycerides.

Key words: Canine Parvovirus enteritis, Hepcidin, Hematology, Serum Biochemistry, Dogs

INTRODUCTION

Gastroenteritis is a vastly common disorder among puppies; in considerable number of cases can be attributed to a highly contagious agent, namely canine parvovirus enteritis "CPV" (Judge, 2015).

CPV is a DNA non-enveloped virus belongs to Parvoviridae (Carr-Smith *et al.*, 1997). The virus has great affinity to invade lymphoid and intestinal tissue, and it is transmitted via fecal-oral means (Prittie, 2004).

Fever, lethargy, vomiting, dehydration and diarrhea which alternated from mucoïd to hemorrhagic are the most common recorded clinical signs associated with CPV (Lamm and Rezabek, 2008; Goddard and Leisewitz, 2010; Tabor, 2011). Suppression in leucocytes, neutrophil and lymphocytes are predicated in this condition (MaCartney *et al.*, 1984, Goddard *et al.*, 2008); while anemia is a frequent finding, however it was thought to be a result of oxidative stress status rather than the virus suppresses erythropoiesis (Panda *et al.*, 2009).

Diagnosis of canine parvovirus enteritis cannot depend solely on clinical signs, as it might be confusing with other

diseases (Goddard and Leisewitz, 2010). Nowadays, the recent development of rapid immune-migration test kit that doesn't need sophisticated equipment and can give rapid in-clinic confirmation of affection within minutes (Shashidhara *et al.*, 2009) was gaining wide acceptance as a method of diagnosis (Salem, 2014).

Lately, a peptide produces from liver under effect of different stimuli under the name of "Hepcidin" gains attention of many researchers (Sahinduran *et al.*, 2016). Hepcidin, acute phase protein "APP" (Nemeth *et al.*, 2003), was considered to have antimicrobial properties only (Park *et al.*, 2001). However, hepcidin was found to play an integral regulatory role in iron metabolism (Nemeth and Ganz 2009). It was also thought that, hepcidin expression is in association with inflammatory conditions as well as decrease with iron deficiency anemia (Theurl *et al.*, 2009).

This study aimed to investigate alterations in clinic-pathological parameters in CPV enteritis as well as alteration in hepcidin level associated with CPV infection to puppies.

MATERIALS AND METHODS

Animals

A total number of 13 puppies of different breeds, with age range of 2months-6months old admitted to small animal clinic, Faculty of Veterinary Medicine, Cairo University, with signs compatible with canine parvovirus enteritis. Another apparently healthy five puppies within similar age range were enrolled as control group.

Clinical examination and sampling

All animals were clinically examined and clinical signs were recorded at time of admission. Fecal samples from affected animals were taken for microscopical examination to ensure animals were parasitological free. In- clinic rapid CPV Ag rapid kits were used on stool of suspected dogs (Quicking Biotech Co, Ltd, Shanghai, China) (Figure 1).

Only the dogs give positive results upon IC- test were enrolled in this study. In the same way, blood samples from all animals were withdrawn and divided into 2 tubes; EDTA-containing tubes were used for clinical hematology. Blood in plain tube was used for serum separation.

Serum biochemistry examination

Sera of affected dogs were used to estimate TP, albumin, triglycerides, BUN and ALP using specified test kits (Spectrum-diagnostic, Egypt). Serum samples used to estimate Hepcidin were stored at -80°C until use.

Determination of hepcidin level

Serum hepcidin levels were determined by Sandwich quantitative ELISA technique using dedicated canine hepcidin (HEPC) ELISA kit (Catalogue # MBS010437; MyBiosource, USA).

Statistical analysis

Data of Parvovirus enteritis affected puppies were compared to data of control group using Student T-test. P value ≤ 0.05 considered of significant value.

RESULTS AND DISCUSSION

Inappetance, depression, pyrexia, vomiting, dehydration and bloody diarrhea were the most observed clinical signs in this study (Figure 1). These symptoms were reported in association with CPV infection (Goddard *et al.*, 2008; Lamm and Rezabek, 2008; Salem, 2014). Though diarrhea might range from mucoid to hemorrhagic; it is mostly attributed to production of cytokines, endotoxemia and epithelia damage of intestinal vasculature (Isagai *et al.*, 1989; Zafar *et al.*, 1999). However, depending on signs only is not confirmatory of diagnosis (Goddard and Leisewitz, 2010).

Alterations in hemato-biochemical parameters are shown in Table 1. Significant reduction in erythrogram was recorded in affected puppies. The recorded anemia in CPV enteritis is doubtful to be the doing of clampdown of bone marrow production, however, the virus was found to cause modifications in erythroid cell-lines (Potgieter *et al.*, 1981; Boosinger *et al.*, 1982). Hemorrhage from intestinal damage may also implicated in PCV reduction (Wazir *et al.*, 2011). In the recent years, the oxidative stress process

associated with viral infection was believed to play a crucial role in anemia (Panda *et al.*, 2009).

Leucogram showed leucopenia, neutropenia and lymphopenia. Parvovirus infection is known to cause devastation to swift dividing cells along with substantial exudation of neutrophils to the damaged intestine (Raskins *et al.*, 2004). CPV has the capability to abolish "active precursor" of circulating WBCs with especially affinity to neutrophils (McCaw and Hoskins, 2006). Lymphocyte reduction was linked to extended hospital stay of ill-dogs (Kalli *et al.*, 2010). Moreover, Mylonakis *et al.*, 2016 attributed the resultant leukopenia, lymphopenia and neutropenia to huge request of inflamed mucosa of intestine along with exhaustion of lymphoid tissue. However, leukocytosis and neutrophilia were also recorded (Goddard *et al.*, 2008).

Slight reduction in TP and albumin were recorded; damage of intestinal villi by the effect of virus might cause a condition of protein-losing enteropathy (Prittie, 2004). Generation of acute phase proteins as a reaction to inflammation and tissue impairment come on the expanse of albumin synthesis (Mazzaferro *et al.*, 2002). ALP showed non-significant elevation compared to control data, and this finding recorded elsewhere (Salem, 2014). Triglycerides and BUN showed significant elevations, these alterations were attributed to modifications in lipid metabolism and acute phase response (Yilmaz and Senturk, 2007; Salem, 2014). Dehydration as a consequence to vomiting and diarrhea might be linked to BUN elevation (Barsanti *et al.*, 2004).

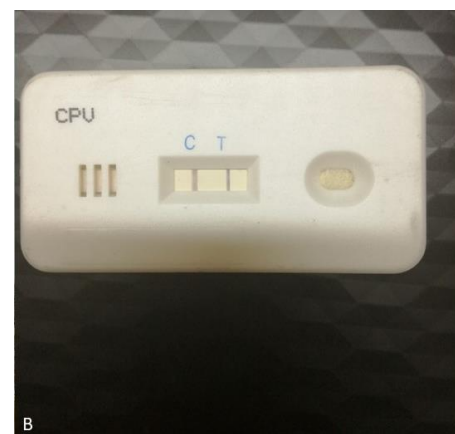
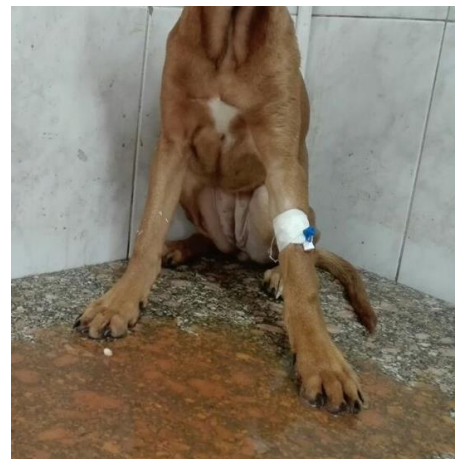


Fig. 1: A) Boxer dog with bloody diarrhea; **B)** IC rapid test kit for detection of CPV Ag showing positive result.

Table 1: Hematologic and biochemical changes in canine parvovirus enteritis compared to control dogs (Mean \pm SEM)

Parameter	Diseased dogs	Control dogs
RBCs	3.955 \pm 0.42*	6.00 \pm 0.15
PCV	34 \pm 1.56*	40.0 \pm 1.38
HB	11.54 \pm 0.57*	14.01 \pm 0.80
WBCs	6.813 \pm 4.75*	12.300 \pm 1.34
Neutrophils	2989 \pm 151.25*	8027 \pm 985
Lymphocytes	1969.09 \pm 218*	3193 \pm 383
TP	5.59 \pm 0.15*	6.54 \pm 0.353
Albumin	2.73 \pm 0.140*	3.380 \pm 0.27
ALP	179.962 \pm 23.52	111.62 \pm 12.7
BUN	21.84 \pm 1.95*	13.63 \pm 1.475
Triglycerides	61.75 \pm 6.02*	33.05 \pm 5.43

*P \leq 0.05.**Table 2:** Hepcidin profile among diseased and control dogs

Hepcidin (ng/ml)	Minimum	maximum	Mean \pm SEM
Diseased	7.864	50.1	30.615 \pm 4.035*
Control	5.348	15.631	10.895 \pm 1.712

*P \leq 0.05.

Significant elevation in serum hepcidin values in CPV enteritis was observed when compared to control data (table 2). Hepcidin reins body iron metabolism (Grimes *et al.*, 2012). Inflammation and/or infection motivate assembly of hepcidin in body (Nemeth *et al.*, 2003). Iron-deficiency anemia is associated with decline in hepcidin levels while infection, inflammation and anemia of inflammation associated with rise in hepcidin level (Ganz, 2011; Grimes *et al.*, 2012). Although hepcidin plays integral role in iron metabolism, it also connected with wide variety of non-hematologic and hematologic affections. CPV enteritis was thought to cause an increase in inflammatory response, namely cytokines (Coskun and Sen, 2012). Moreover, Sahinduran *et al.*, 2016 attributed elevation of hepcidin level in association with CPV enteritis to the marked elevation of IL-1, IL-6 and TNF in response to viral infection, endotoxemia, sepsis in correlation with secondary infections and mucosal damage. Furthermore, inflammatory reaction stimulates IL-6 release during sepsis and inflammatory conditions (Kali *et al.*, 2015).

Conclusion

In canine parvovirus enteritis, Canine hepcidin level has a tendency to rise during the clinical illness along with anaemia, leukopenia and reduction in protein level.

REFERENCES

Barsanti JA, GE Lees, MD Willard and RA Green, 2004. Urinary disorders. In: Willard MD and Tvedten H (editor), Small Animal Clinical Diagnosis by Laboratory Methods. 4th ed., Saunders.

Boosinger, TR, AH Rebar, DB Denicolo, and GD Boon, 1982. Bone marrow alterations associated with canine parvo viral enteritis. *Vet Pathol*, 19(5): 558-561.

Carr-Smith S, DK Macintire, LJ Swango, 1997. Canine parvovirus: Part 1. Pathogenesis and Vaccination. *Comp Cont Ed Pract Vet*, 19(2):125-133.

Coskun A, and İ Sen, 2012. Haematological, Biochemical and coagulation changes in calves with endotoxemia. *Agric J*, 7: 37-41.

Ganz T, 2011. Hepcidin and iron regulation, 10 years later. *Blood*, 117: 4425-4433

Goddard A and AL Leisewitz, 2010. Canine Parvovirus. *Vet Clin North Am - Small Anim Pract*, 40: 1041-1053.

Goddard A, AL Leisewitz, MM Christopher, NM Duncan and PJ Becker, 2008. Prognostic usefulness of blood leukocyte changes in canine parvoviral enteritis. *J Vet Intern Med*, 22: 309-16.

Grimes CN, L Giori and MM Fry, 2012. Role of hepcidin in iron metabolism and potential clinical applications. *Vet Clin Small Ann*, 42: 85-96.

Isogai E, H Isogai, M Onuma, N Mizukoshi, M Hayashi and S Namioka, 1989. Escherichia coli associated endotoxemia in dogs with parvovirus infection. *Nihon Juigaku Zasshi*, 51: 597-606.

Judge P, 2015. Management of the Patient with Canine Parvovirus Enteritis. *Vet Education*, proceedings of the New Zealand veterinary nursing association annual conference, 5-11

Kali A, MV Charles, and RS Seetharam, 2015. Hepcidin-A novel biomarker with changing trends. *Pharmacogn Rev*, 9: 35-40.

Kalli I, LS Leontides, ME Mylonakis, K Adamama-Moraitou, T Rallis and AF Koutinas, 2010. Factors affecting the occurrence, duration of hospitalization and final outcome in canine parvovirus infection. *Res Vet Sci*, 89: 174-178.

Lamm CG and GB Rezabek ,2008. Parvovirus infection in domestic companion animals. *Vet Clin North Am Small Anim Pract*, 38: 837-850.

MaCartney L, IA McCandlish, H Thompson and HJ Cornwell, 1984. Canine parvovirus enteritis I: clinical, haematological and pathological features of experimental infection. *Vet Rec* ,115: 201-10.

Mazzaferro EM, E Rudleff and R Kirby, 2002. The role of albumin replacement in the critically ill veterinary patient. *J Vet Emerg Crit Care*, 12: 113-124.

McCaw DL and JD Hoskins, 2006. Canine parvovirus. In: Greene CE (editor). *Infectious Diseases of the Dog and Cat*. 3rd ed., Saunders, pp: 63-73

Mylonakis M, I Kalli and T Rallis, 2016. Canine parvoviral enteritis: an update on the clinical diagnosis, treatment, and prevention. *Veterinary Medicine: Research and Reports*, 7: 91-100. doi: 10.2147/VMRR.S80971.

Nemeth E, EV Valore, M Territo, G Schiller, A Lichtenstein and T Ganz, 2003. Hepcidin, a putative mediator of anemia of inflammation, is a type II acute-phase protein. *Blood*, 101(7): 2461-2463.

Nemeth E and T Ganz, 2009. The role of hepcidin in iron metabolism. *Acta Haematol.*, 122: 78-86.

Panda D, RC Patra, S Nandi and D Swarup, 2009 . Oxidative stress indices in gastroenteritis in dogs with canine parvoviral infection. *Res Vet Sci*, 86: 36-42.

Park CH, EV Valore, AJ Waring and T Ganz, 2001. Hepcidin, a urinary antimicrobial peptide synthesized in the liver. *J Biol Chem*, 276: 7806-7810.

Potgieter LND, JB Jones, GS Patton and TA Webb-Martin, 1981. Experimental Parvovirus infection in dogs. *Can J Comp Med*, 45: 212-216.

Prittie J, 2004. Clinical Practice Review Canine parvoviral enteritis: a review of diagnosis, management, and prevention. *J Vet Emerg Crit Care*, 14: 167-176.

- Raskins RE, KS Latimer, and H Tvedton, 2004. Leucocyte disorder, In: Willard MD and Tvedten H (editor), *Small Animal Clinical Diagnosis by Laboratory Methods*. 4th ed., Saunders.
- Sahinduran S, MK Albay, MC Karakurum, O Ozmen and M Kale, 2016. Investigation of some cytokines, acute phase proteins and hepcidin levels before and after treatment in dogs with parvoviral gastroenteritis. *Pak Vet J*, 36(4): 487-492.
- Salem NY, 2014. Canine Viral Diarrhea: Clinical, Hematologic and Biochemical Alterations with Particular Reference to In-Clinic Rapid Diagnosis. *Global Veterinaria*, 13(3): 302–307.
- Shashidhara Y, M Kapil and S Kapil, 2009. Simple tests for rapid detection of canine parvovirus antigen and antibodies. *Clinical and Vaccine Immunology J*, 16: 127-131.
- Tabor B, 2011. Canine Parvovirus. *Comp Cont Educ Vet Tech*, E1-E9. http://vetfolio-vetstreet.s3.amazonaws.com/2a/c3dfa0a9a611e087120050568d3693/file/_Tabor_CE.pdf
- Theurl I, E Aigner , M Theurl , M Nairz , M Seifert , A Schroll , T Sonnweber , L Eberwein , DR Witcher , AT Murphy , VJ Wroblewski , E Wurz , C Datz and G Weiss, 2009 .Regulation of iron hemeostasis in anemia of chronic disease and iron deficiency anemia: diagnostic and therapeutic implications. *Blood*, 113:5277-5286.
- Wazir VS, SK Gupta, RK Bhardwaj, AK Taku, JS Soodan, SK Kotwal, R Singh and VP Singh, 2011. clinic-hematological alterations in CPV gastroenteritis in canines. *Proceedings of 29th ISVM Convention and National Symposium on "Recent Developments in Diagnostics and Therapeutics Including Applications of Nano-Technology in Veterinary Medicine"*. 17th - 19th February 2011.
- Yilmaz Z and S Senturk, 2007. characterization of lipid profiles in dogs with parvovirus enteritis. *Journal of Small Animal Practice*, 48: 643-650.
- Zafar MS, SA Khan and A Rabbani, (1999): Hematological studies and estimation of electrolytes in dogs exhibiting diarrhoeal signs. *Pak Vet J*, 19: 35-39.